

Case Report

© 2024 Stern et al

Submitted: 14-08-2023

Accepted: 29-02-2024

License: This work is licensed under a [Creative Commons Attribution 4.0 International License](https://creativecommons.org/licenses/by/4.0/).

DOI: <https://doi.org/10.47338/jns.v13.1244>

Double-blind ureteral duplication- a rare cause of a neonatal abdominal cyst: A case report

Maria Vittoria Stern,^{1*} Filomena Valentina Paradiso,¹ Riccardo Rizzo,¹ Sara Silvaroli,¹ Francesco Pierconti,² Lorenzo Nanni¹

1. Pediatric Surgery Unit, Department of Maternal and Child Health and Public Health. Fondazione Policlinico Universitario Agostino Gemelli, IRCCS, Rome, Italy

2. Pathology Unit, Department of Woman and Child Health and Public Health. Fondazione Policlinico Universitario Agostino Gemelli, IRCCS, Rome, Italy

Correspondence*: Maria Vittoria Stern, Pediatric Surgery Unit, Department of Maternal and Child Health and Public Health. Fondazione Policlinico Universitario Agostino Gemelli, IRCCS, Rome, Italy.

E-mail: mariavittoria.stern@gmail.com

KEYWORDS

Double-blind ureteral duplication,
Neonate,
Abdominal cyst

ABSTRACT

Background: Double-blind ureteral duplication (DBUD) is a rare condition in which one of the ureters in a duplicated system has no communication with the bladder or the renal pelvis.

Case Presentation: We present a neonatal case of DBUD in a newborn girl, associated with a non-functional kidney, initially identified as an abdominal cystic anechoic mass during antenatal ultrasound. A stepwise diagnostic and management approach was undertaken, including prenatal and postnatal imaging, multidisciplinary consultation, and surgical intervention.

Conclusion: Establishing a diagnosis of DBUD requires a systematic approach, incorporating comprehensive prenatal and postnatal assessments. This case is the first reported instance of DBUD diagnosed and treated in the neonatal period, highlighting the importance of early detection and intervention.

INTRODUCTION

Double-blind ureteral duplication (DBUD) is a rare condition in which one of the ureters of a duplicated system shows no communication with the bladder or the renal pelvis. In some cases, there may be a connection with the normal ureter in the mid-portion [1].

DBUD is mostly diagnosed in adult patients or in children when it becomes symptomatic. In these cases, surgical excision is recommended to avoid complications such as lithiasis, urinary tract infection, or symptoms of intestinal obstruction. No cases of DBUD diagnosed and treated in the neonatal period are reported in the literature. The present case is different from those reported in the literature because the DBUD did not show communication with either the normal ureter or the bladder, and it was associated with a non-functioning kidney.

We emphasize the importance of a preoperative assessment to establish a precise diagnosis and to plan a suitable surgical treatment.

CASE REPORT

A female baby was delivered at post-term gestation (39+1 weeks) with a birth weight of 3465 grams. An

antenatal ultrasound (US) performed at 26 weeks gestation showed a cystic anechoic mass associated with pyelectasis in her right flank region; the anterior-posterior diameter (APD) of the renal pelvis was 13 mm. The baby had normal intrauterine growth. These findings were confirmed in all her three follow-up US examinations.

At 37+2 weeks' gestational age, the right kidney showed a normal appearance, with dimensions of 35x36x49 mm. The anechoic lesion, 42x84 mm in diameter, occupied the right flank, extending from the kidney to the bladder. The left kidney showed normal characteristics and dimensions (36x38x57 mm), with a dilated pelvis (14 mm APD) and mild calycectasis.

Differential diagnoses (DD) were discussed during a multidisciplinary counseling session involving a gynecologist, neonatologist, pediatric surgeon, and psychologist. Possible diagnoses included intestinal duplication, lymphangioma, right megaureter, and ureteral duplication (UD). The parents were informed about the diagnostic, therapeutic, and prognostic characteristics of each of these conditions.

At birth, the baby had a normal extrauterine adaptation, passing meconium and urine regularly

within 24 hours. She developed abdominal distension 24 hours after birth. A tender, right-sided abdominal mass was palpable. The external genitalia were normal. Her serum biochemistry was normal. An abdominal X-ray ruled out intestinal dilatation or intestinal perforation.

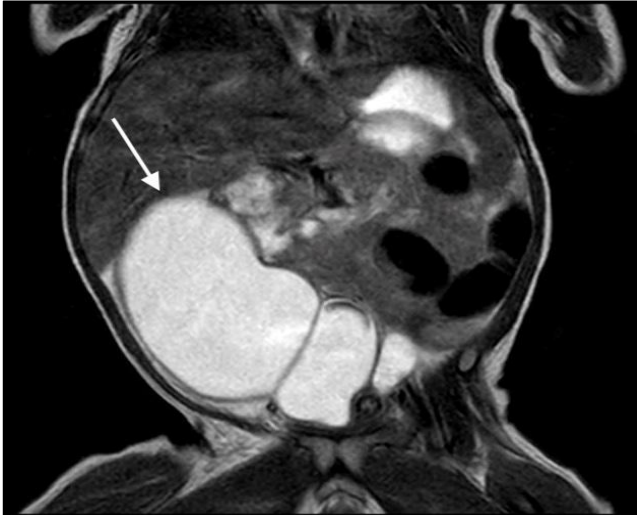

Figure 1: Coronal view of the pre-operative MRI showing a fluid filled mass with regular wall extending from the right hypochondrium to the pelvic floor (white arrow).

The abdominal US done 48 hours after birth showed a huge cyst-like anechoic mass in the right abdomen extending from the flank to the pelvic floor; the maximum APD was 4 cm, and the cranio-caudal extension was 10 cm. Some smaller contiguous components of the cyst were documented close to the renal hilum and pelvis. This lesion displaced and compressed the right kidney, and the renal parenchyma appeared diffusely non-homogeneous. Left hydronephrosis was documented (APD 12 mm). No ureteral dilations were evidenced bilaterally.

Magnetic Resonance Imaging (MRI) confirmed the massively dilated tubular lesion (42x35x92 mm) with fluid content and regular walls, extending from the right hypochondrium to the pelvic floor lateral to the bladder. This cyst compressed the fifth and sixth hepatic segments and displaced the right kidney posteriorly (Fig. 1). A minimal dilatation of the calyces and the proximal right ureter was also present. The left renal parenchyma showed a thinned and hyperintense appearance with marked dilation of the calyces, the pelvis (APD 11 mm), and the ureter throughout its course (maximum diameter 6 mm).

These findings were concordant with a right retroperitoneal cystic mass that probably originated from the urinary tract but without any connection to it.

At 15 days of life, a voiding cystourethrography (VCUG) showed a normal bladder with no ureterocele

or passive or active vesicoureteral reflux (VUR). Since connection with the urinary tract had been excluded, a laparotomy was performed.

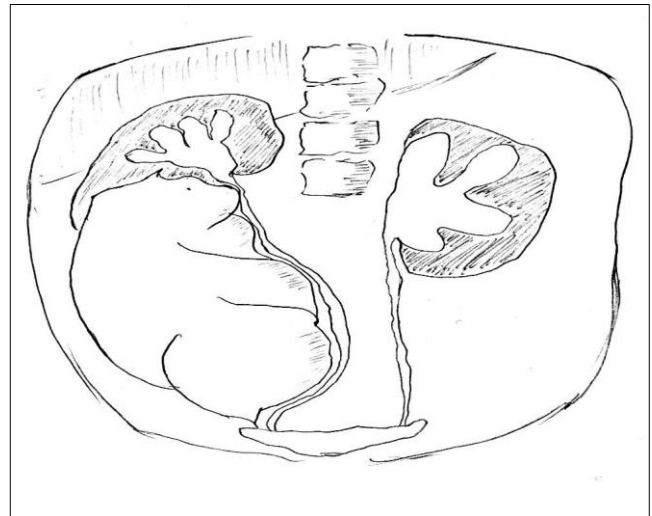


Figure 2: Intraoperative illustration: The proximal blind end of the lesion was connected to the posterior aspect of the right pelvis, using a fibrotic string; the distal blind-ending, also consisting of an atretic cord, was attached to the pelvic floor without any connection to the bladder.

At surgical exploration, the lesion was found in the retroperitoneum and presented features of a huge, dilated ureter (Fig. 2). The proximal blind end of the lesion was connected to the posterior aspect of the right pelvis by a fibrotic string; the distal blind end, also consisting of an atretic cord, was attached to the pelvic floor without any connection to the bladder. During dissection, no connection between the cyst and the urinary tract was found. The right ureter was dissected free along its entire course and was not dilated. No other anomalies were found during surgery. The uterus and adnexa were normal without any connection to the cyst. The cyst contained clear fluid.

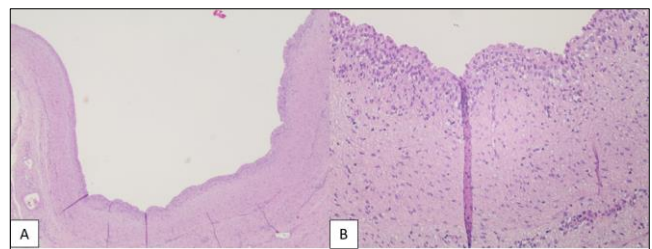


Figure 3: Histological confirmation of urothelium. A) The ureteral wall appears thinned and ectatic at microscopic evaluation (Hematoxylin-eosin stain; 2X). B) At higher microscopic magnification, no atypia of the urothelium were found (Hematoxylin-eosin stain; 10X)

Histology confirmed the ureteral nature of the lesion; the definitive diagnosis was DBUD. Hematoxylin-eosin staining showed a normal urothelium without cellular atypia (Fig. 3). Furthermore, urothelium-specific staining (CK7 and GATA3 antibodies) was positive (Fig. 4). The baby had an uneventful

postoperative course and was discharged home four days later.

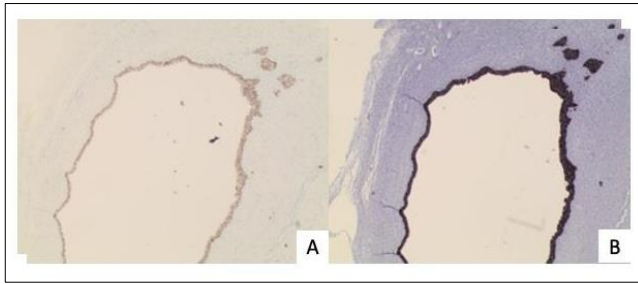


Figure 4: Histological confirmation of urothelium. A) Antibodies GATA 3 were confirmed (GATA 3 stain; 2X). B) Antibodies CK7 were confirmed (CK7 stain; 2X).

Four months after surgery, a repeat MRI was performed to reassess the anatomy of the remaining right renal parenchyma. The right pelvis and ureter appeared normal, but multiple small cysts were reported in the inferior pole of the ipsilateral kidney (Fig. 5). Due to the abnormal appearance of the inferior half of the right kidney, MAG3 renal scintigraphy (RS) was performed. A markedly reduced right renal function was documented due to a combined defect in the uptake and excretion of the radiotracer, even after furosemide administration.

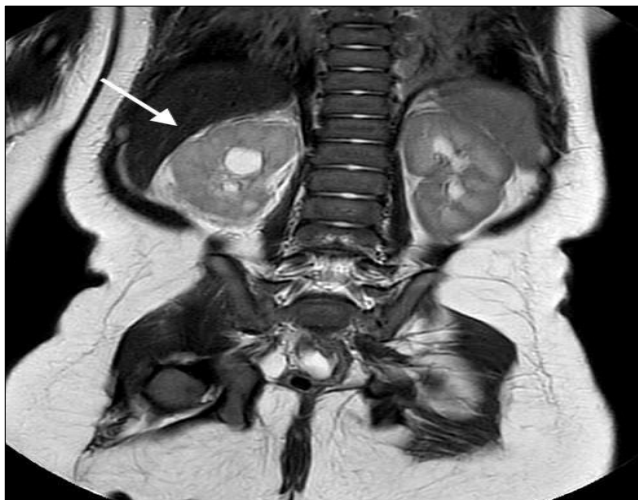

Figure 5: Post-operative MRI: coronal view. The right pelvis and ureter appeared normal (white arrow).

At a 10-month follow-up, she is asymptomatic with normal serum creatinine. No UTI episodes have been reported. The US showed a normal left kidney with no ureteral dilatation. She will be followed with periodic assessments of renal function. If UTI episodes develop during infancy, a repeat RS will likely be necessary to discuss the possible indication for right nephrectomy.

DISCUSSION

Double-blind ureteral duplication (DBUD) is a rare malformation, with only a few cases reported in the literature. In most cases, patients are symptomatic, and diagnosis is obtained during adult life (3rd-4th

decade of age) or in childhood. A right-sided and female predominance has been described [1-3]. Common symptoms include abdominal or chronic flank pain, sometimes complicated by urinary tract infections or lithiasis.

DBUD was first reported by Herbert in 1904 [4]. Since then, many theories have been proposed to explain the origin of DBUD. The most widely accepted theory is the presence of an abnormal ureteral bud. During the 28th week of gestation, the ureteral bud arises from the mesonephric duct (MD) proximally and connects to the metanephric mesenchyme (MM). Development occurs through reciprocal induction of these two structures: the ureteral bud gives rise to the collecting system, while the MM develops into the renal parenchyma (glomerulus, proximal tubule, loop of Henle, and distal tubule) [5]. Dysregulation of this process may result in the formation of two separate ureteral buds arising from the MD, from which a UD originates.

UD is the most common ureteral anomaly and affects both sides equally; girls are affected twice as often as boys. Many UDs are associated with dysplastic renal parenchyma or hydronephrosis [6]. Among UDs, the blind-ending ureter (BEU) is the rarest condition. As Choi et al. postulated, the BEU is due to a duplicated ureteral bud that failed to connect with the MM, resulting in a blind proximal ending [1].

In DBUD, the distal end also terminates abruptly and lacks connection with the urinary tract. To explain the distal atresia, we agree with some authors who suggested that an ischemic event in the distal part of the ureter during prenatal life can explain this condition. The timing of the distal ureteral ischemia may explain the fluid filling of DBUD [1, 2].

To our knowledge, the present case of DBUD is the first described in a neonate and suspected during prenatal diagnosis. Differential diagnosis of fluid-filled cystic masses should include retroperitoneal cystic lymphangioma, intestinal duplication, obstruction of the upper moiety of UD, or megaureter.

Typical features of lymphangiomas during prenatal US are anechoic, multilocular cysts with septations. They are commonly located in the head or neck and less frequently involve the mesentery or the retroperitoneum [7]. Intestinal duplication shows a typical US “double wall sign” consisting of an outer hypoechoic muscular layer, an internal echogenic mucosal layer, and corpuscular fluid inside the lesion [8]. Post-natal MRI and VCUG are useful tools to discern the ureteral nature of the lesion. In the present case, MRI showed that the mass lacked any connection with the urinary tract, while the right normal ureter was documented along its entire

course. Finally, the absence of VUR or ureteroceles ruled out complete UD.

When DBUD is suspected, a possible reduction in renal function must be considered, and an RS should

be performed preoperatively to plan surgery appropriately. In the present case, due to feeding difficulties and an intervening septic episode, surgery was performed before any data on kidney function could be obtained. Table 1 shows cases of DBUD.

Table 1: A literature review of cases of DBUD

	Age	Sex	Symptoms	Preoperative assessment	Treatment	Follow up
Hulett et al (1997)	11 yrs.	M	Abdominal pain	US, CT, VCU, RGP	Surgical excision	NR
Choi et al (2002)	36 yrs.	F	no	US, CT, RGP, and Cystoscopy	Surgical excision	NR
Choi et al (2002)	45 yrs.	F	generalized edema and general weakness of 1-month duration	US, CT, RGP, and Cystoscopy	Surgical excision	NR
Salakos et al (2009)	8 yrs.	F	no	US, CT, renal scintigraphy, MRI, cystoscopy and vaginostomy	Surgical excision	NR

Legend: Male (M); Female (F); Ultrasonography (US); voiding cystourethrography (VCU), retrograde pyelography (RGP), computed tomography (CT), Magnetic Resonance Imaging (MRI), Not Reported (NR)

In conclusion, DBUD is a very rare condition, mostly diagnosed in adult patients or children when it becomes symptomatic. During antenatal counseling for a fluid-filled, anechoic cystic mass, the diagnosis of DBUD should be considered, and parents must be informed that the condition may be associated with a non-functioning kidney. A complete preoperative assessment with MRI, VCUG, and RS is mandatory to confirm the precise diagnosis.

Acknowledgements: Nil

Conflict of Interest: None.

Source of Support: Nil

Consent to Publication: Author(s) declared taking informed written consent for the publication of clinical photographs/material (if any used), from the legal guardian of the patient with an understanding that every effort will be made to conceal the identity of the patient, however it cannot be guaranteed.

Author Contributions: Author(s) declared to fulfil authorship criteria as devised by ICMJE and approved the final version.

REFERENCES

- Choi JY, Kim S, Kim S. Double-blind ureteral duplication: report of two cases. *Eur Radiol.* 2002;12:S136-9.
- Hulett RL, Ozgur HT. Double blind ureteral duplication. *Pediatr Radiol.* 1997;27(6):561.
- Salakos C, Tyrizis SI, Papanastasiou D, Geropoulou E, Constantinides CA. Double-blind ureteral duplication: a rare urologic anomaly. *Urology.* 2009;73(1):210-e1.
- Herbert H. Diverticule de l'uretère. *Bull Med Soc Anat Paris.* 1904;6:76.
- Cuckow PM, Nyirady P, Winyard PJ. Normal and abnormal development of the urogenital tract. *Prenatal Diagnosis: Published in Affiliation With the International Society for Prenat Diagn.* 2001;21(11):908-16.
- Holcomb W. George e Murphy J. Patrick et. al. Ureteral Obstruction and Malformations. In: Holcomb and Ashcraft's Pediatric Surgery, 7th edition. Elsevier, 2020: 843-4.
- Mostofian E, Ornvold K, Latchaw L, Harris RD. Prenatal sonographic diagnosis of abdominal mesenteric lymphangioma. *J Ultrasound Med.* 2004;23(1):129-32.
- Cheng G, Soboleski D, Daneman A, Poenaru D, Hurlbut D. Sonographic pitfalls in the diagnosis of enteric duplication cysts. *Am J Roentgenol.* 2005;184(2):521-5.