

## Prolapsed Mystery: A Rare Encounter with Uterine Adenosarcoma

Dr. Ramya Baskaran<sup>1</sup>, Dr. Parimala A.<sup>2\*</sup>

<sup>1</sup>Final Year Post Graduate, Department of Obstetrics and Gynaecology, Saveetha Medical College and Hospital, Saveetha Nagar, Thandalam, Chennai - 602105, Tamil Nadu, India

Email ID: [baskaranramaya27@gmail.com](mailto:baskaranramaya27@gmail.com)

<sup>2</sup>Associate professor, Department of Obstetrics and Gynaecology, Saveetha medical college and hospital, Saveetha Nagar, Thandalam, Chennai - 602105, Tamil Nadu, India

### \*Corresponding Author:

Dr. Parimala A.,

Associate professor, Department of Obstetrics and Gynaecology, Saveetha medical college and hospital, Saveetha Nagar, Thandalam, Chennai - 602105, Tamil Nadu, India

Cite this paper as: Dr. Ramya Baskaran, Dr. Parimala A., (2025) Prolapsed Mystery: A Rare Encounter with Uterine Adenosarcoma *Journal of Neonatal Surgery*, 14 (25s), 106-109

### ABSTRACT

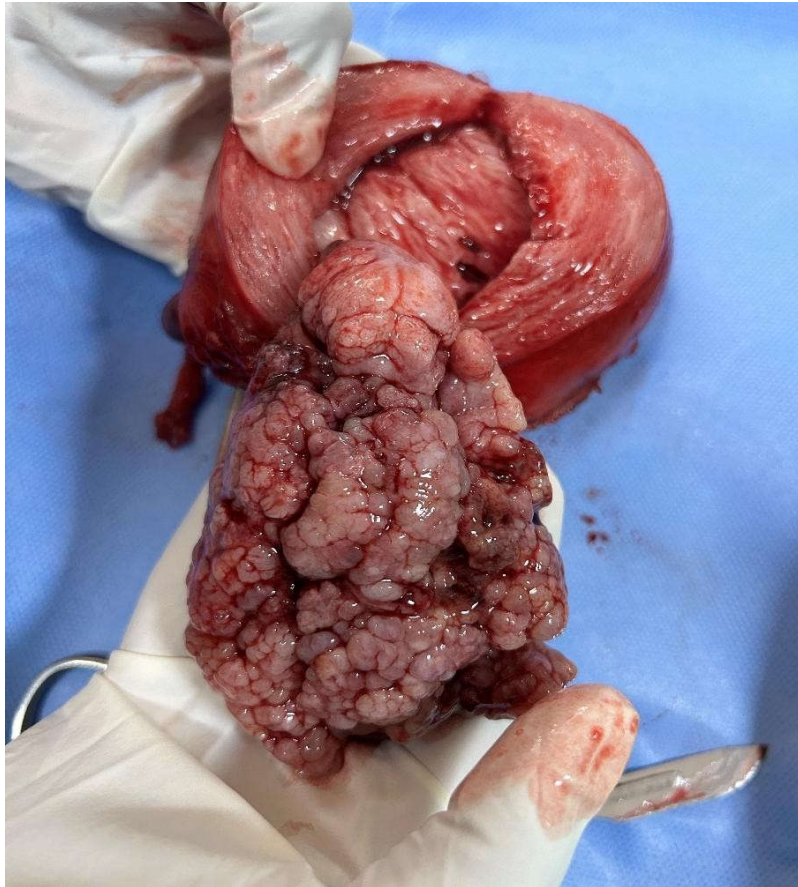
Uterine adenosarcoma is a rare mixed Müllerian tumor with both benign glandular and malignant stromal components. We present a case of a 55-year-old female with abnormal uterine bleeding, initially misdiagnosed as fibroids, later confirmed as uterine adenosarcoma on histopathology. Management involved total hysterectomy with bilateral salpingo-oophorectomy, followed by adjuvant therapy. This report reviews diagnostic challenges, treatment strategies, and prognostic factors, emphasizing the need for early recognition and tailored therapy.

### 1. INTRODUCTION

Uterine adenosarcoma is an uncommon malignancy, accounting for approximately 5-10% of uterine sarcomas, with an incidence of 0.2–0.3 per 100,000 women [1]. First described by Clement and Scully in 1974, it is characterized by a biphasic morphology, combining benign epithelial elements and a low-grade sarcomatous stroma [2]. Despite its typically indolent behavior, sarcomatous overgrowth (SO) and heterologous elements confer a worse prognosis, with recurrence rates up to 40% [3]. The clinical presentation is nonspecific, often mimicking benign conditions such as endometrial polyps or fibroids, leading to delayed diagnosis [4]. Abnormal uterine bleeding (AUB) and pelvic pain are the most common symptoms, while imaging findings are frequently inconclusive [5]. Definitive diagnosis relies on histopathology, where the hallmark feature is a periglandular stromal cuffing with leaf-like architecture resembling phyllodes tumors [1]. Treatment primarily involves surgical resection, typically total hysterectomy with or without bilateral salpingo-oophorectomy (BSO) [2]. The role of lymphadenectomy remains controversial, as lymph node metastasis is rare (<5%), though some studies suggest improved survival with lymph node assessment in high-risk cases [3]. Adjuvant therapy (chemotherapy or radiation) is reserved for advanced-stage disease or sarcomatous overgrowth, but evidence is limited due to the rarity of the disease [9]. This case report highlights diagnostic pitfalls, therapeutic decision-making, and a review of current literature to guide clinical management.

### CASE DETAILS

A 55-year-old postmenopausal woman presented with complaints of continuous abnormal uterine bleeding for the past one month. She had attained menopause 13 years prior. The bleeding was associated with the sensation of a mass protruding through the vagina. On per speculum examination, a polypoidal growth was observed emerging through the cervical os. Per vaginal examination revealed a cervix pointing downward and a uterus of approximately 10–12 weeks in size, bilaterally free and non-tender. Cervical and endometrial biopsies were performed. Cervical biopsy showed chronic papillary endocervicitis, while the endometrial biopsy indicated disordered proliferative endometrium.

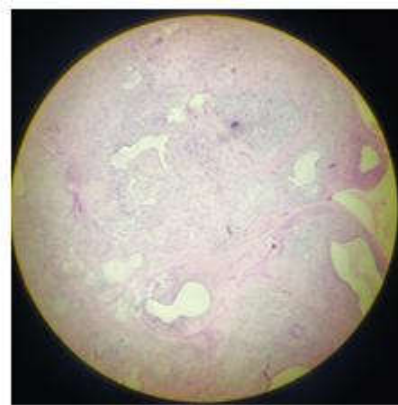
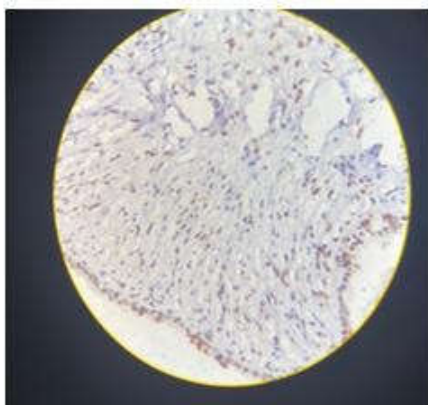


MRI of the pelvis revealed a bulky uterus with a thickened and heterogeneous endometrium, measuring approximately 52 mm. The features were suggestive of endometrial hyperplasia with a potential risk of malignant transformation.

The patient underwent total abdominal hysterectomy with bilateral salpingo-oophorectomy, infracolic omentectomy, and peritoneal wash, along with excision of a vaginally prolapsed cervical growth.

#### Histopathology Findings:

- **Diagnosis:** Uterine Adenosarcoma, Not Otherwise Specified (NOS)
- **Tumor Grade:** Low-grade
- **Pathological Stage:** pT1b pN0 (FIGO Stage IB)
- **Margins:** All surgical margins were negative for tumor infiltration
- **Sarcomatous Overgrowth:** Absent



#### Immunohistochemistry Profile:

- **Estrogen Receptor (ER):** Strong nuclear positivity in 90% of epithelial cells and 80% of stromal cells
- **Progesterone Receptor (PgR):** Strong nuclear positivity in 80% of epithelial cells and 70% of stromal cells
- **CD10:** Positive in 60% of stromal cells
- **Ki-67 Index:** Approximately 5%

The findings were consistent with a diagnosis of low-grade uterine adenosarcoma, with no evidence of high-risk features such as sarcomatous overgrowth or lymphovascular invasion. The patient was scheduled for regular postoperative follow-up without adjuvant therapy, considering the early stage and favorable histopathological characteristics.

## 2. DISCUSSION

Uterine adenosarcoma is a rare and complex neoplasm characterized by the presence of both benign epithelial elements and a malignant sarcomatous stromal component. It falls under the category of mixed epithelial and mesenchymal tumors, with an overall low incidence. These tumors account for approximately 5%–10% of uterine sarcomas and only about 1% of all gynecologic malignancies. While it more commonly presents in postmenopausal women, it can also occur in younger patients, making awareness of its varied presentation critical for early diagnosis and effective management. In the present case, a 55-year-old postmenopausal woman presented with abnormal uterine bleeding of one-month duration and a mass protruding through the vagina. This presentation is not uncommon in uterine adenosarcomas, which often manifest as abnormal uterine bleeding, pelvic pain, and occasionally, prolapsed polypoidal growths through the cervical os. The postmenopausal status and age of the patient fall within the typical demographic range reported in literature, where the mean age at diagnosis is generally between 50 and 60 years. However, the disease can affect a much broader age group, and its presentation can mimic more benign conditions like endometrial polyps or submucosal fibroids, leading to potential misdiagnosis if not thoroughly investigated. Al-Talib et al. reported a case of uterine adenosarcoma in a 19-year-old woman, making it a particularly unusual occurrence due to the patient's young age and nulliparity. The patient had presented with irregular bleeding and a friable mass extending into the vaginal canal. As in our case, the diagnosis was not immediately apparent, and multiple investigations, including biopsies and imaging, were required to confirm the malignancy. The young patient underwent total abdominal hysterectomy with bilateral salpingo-oophorectomy and lymph node assessment. Postoperatively, she received adjuvant radiotherapy and chemotherapy, and was reported to be disease-free 40 months after treatment, illustrating that even in younger patients, early surgical intervention followed by appropriate adjuvant therapy can yield favorable outcomes [6].

In contrast, another case reported by Huang et al. involved a 38-year-old woman with similar symptoms of abnormal vaginal bleeding. Initial imaging suggested a heterogeneous endometrial mass. She underwent hysteroscopic resection followed by total abdominal hysterectomy with bilateral salpingo-oophorectomy and pelvic lymphadenectomy. Histopathological analysis confirmed uterine adenosarcoma. The patient subsequently received six cycles of chemotherapy. Her post-treatment course was uneventful, and she remained disease-free after 15 months of follow-up. This case reinforces the importance of complete surgical excision and highlights the potential role of chemotherapy in patients with high-risk features or deep myometrial invasion [7]. In a different clinical scenario, Sadat et al. presented a case involving a 46-year-old woman diagnosed with uterine adenosarcoma with sarcomatous overgrowth. Unlike low-grade tumors, adenosarcomas with sarcomatous overgrowth are known for their aggressive behavior, increased recurrence rates, and poorer prognosis. In this case, the tumor originated in the lower uterine segment and showed malignant heterologous elements such as rhabdomyosarcomatous differentiation. The patient underwent surgical resection, and histopathological analysis revealed high-grade features. This case emphasizes the need to carefully evaluate for sarcomatous overgrowth, which significantly influences treatment decisions and prognosis [8]. In another noteworthy case, Nishio et al. described the management of a patient with residual disease following surgery for uterine adenosarcoma. The patient underwent four cycles of adjuvant chemotherapy with Ifosfamide, Mesna, and Adriamycin, followed by whole pelvic radiation therapy. This multimodal approach was adopted due to the presence of residual tumor and other high-risk features. The case illustrates that in patients where surgical margins are positive or when residual disease is suspected, adjuvant therapy, including chemotherapy and radiotherapy, can be considered to reduce the risk of recurrence [9]. When compared to the above cases, our patient had several favorable prognostic indicators. Firstly, there was no evidence of sarcomatous overgrowth on histopathological examination. This is significant because sarcomatous overgrowth, defined as a high-grade sarcomatous component comprising more than 25% of the tumor, is associated with increased recurrence and decreased survival. Secondly, immunohistochemistry revealed strong positivity for estrogen and progesterone receptors in both the epithelial and stromal components. The presence of hormone receptor expression is considered a favorable prognostic feature and may also suggest a potential role for hormonal therapy in selected cases. Additionally, the Ki-67 labeling index was approximately 5%, indicating a low proliferative index and correlating with the tumor's low-grade nature. The final pathological staging was FIGO stage IB, with a tumor confined to the uterus and involving more than half of the myometrium but without lymph node metastasis or extrauterine spread. Surgical margins were negative, and there was no lymphovascular invasion. Given the absence of high-risk features, the multidisciplinary team decided against adjuvant chemotherapy or radiation, opting instead

for regular surveillance. This management approach aligns with current guidelines from the National Comprehensive Cancer Network (NCCN), which recommend total hysterectomy with bilateral salpingo-oophorectomy as the standard treatment for uterine adenocarcinoma. Lymphadenectomy is not routinely performed unless there is clinical or radiological suspicion of lymph node involvement, given that lymphatic spread is relatively uncommon in low-grade tumors. Hormonal therapy may be considered in hormone receptor-positive cases, especially in recurrent or inoperable disease, although its role remains less well-defined. Our case, therefore, highlights several important clinical considerations. First, the need for a high index of suspicion in patients presenting with postmenopausal bleeding and atypical uterine masses, even when initial findings suggest benign pathology. Second, it emphasizes the critical role of comprehensive histopathological evaluation, including immunohistochemical staining, in determining the tumor's grade and guiding treatment decisions. Third, it supports the principle of tailoring management based on individual risk stratification—reserving adjuvant therapy for cases with poor prognostic indicators while avoiding overtreatment in low-risk patients. In conclusion, while uterine adenocarcinoma remains a rare entity, accumulating case reports contribute valuable insights into its diverse clinical behavior and management strategies. Our case adds to the growing body of literature supporting conservative management with close follow-up in early-stage, low-grade tumors without sarcomatous overgrowth. Continued documentation and analysis of such cases will help refine treatment protocols and potentially identify molecular targets for therapy in recurrent or advanced disease.

### 3. CONCLUSION

Uterine adenocarcinoma, though rare, should be considered in the differential diagnosis of postmenopausal bleeding and uterine masses, particularly when patients present with polypoidal growths or persistent symptoms unresponsive to conventional treatment. This case underscores the importance of thorough clinical evaluation, imaging, and histopathological confirmation—including immunohistochemical analysis—for accurate diagnosis and appropriate staging. Surgical management remains the cornerstone of treatment, with total hysterectomy and bilateral salpingo-oophorectomy being the standard approach. In cases lacking high-risk features such as sarcomatous overgrowth, lymphovascular invasion, or deep myometrial infiltration, adjuvant therapy may be safely avoided in favor of vigilant surveillance. Our case adds to the growing body of literature supporting individualized treatment planning based on tumor biology and staging. Continued reporting of similar cases will enhance understanding of prognostic indicators and help refine management strategies, particularly for advanced or recurrent disease.

### REFERENCES

- [1] Kanthan R, Senger JL, Diudea D. Uterine adenocarcinoma: a review. *Curr Oncol*. 2016;23(2):e150-e156. [PubMed: 27022319]
- [2] Clement PB, Scully RE. Müllerian adenocarcinoma of the uterus: a clinicopathologic analysis of 100 cases with a review of the literature. *Hum Pathol*. 1990;21(4):363-381. [PubMed: 2180774]
- [3] Nathanson MJ, Ravi V, Fleming N, Wang WL, Conley A. Uterine adenocarcinoma: a review. *Curr Oncol Rep*. 2016;18(11):68. [PubMed: 27671993]
- [4] Arend R, Bagaria M, Lewin SN, et al. Long-term outcome and natural history of uterine adenocarcinomas. *Gynecol Oncol*. 2010;119(2):305-308. [PubMed: 20708275]
- [5] Tanner EJ, Toussaint T, Leitao MM, et al. Management of uterine adenocarcinomas with and without sarcomatous overgrowth. *Gynecol Oncol*. 2013;129(1):140-144. [PubMed: 23385136]
- [6] Al-Talib A, Tulandi T, Goffin F, Gilks B, Bedaiwy MA. Uterine adenocarcinoma in a 19-year-old woman: a case report and literature review. *J Pediatr Adolesc Gynecol*. 2001 May;14(2):87-90. PMID: 11321498.
- [7] Huang J, Lin T, Zhang J, Chen J, Zhang Y, Bai H. Uterine adenocarcinoma: a case report and literature review. *J Int Med Res*. 2023 May;51(5):3000605231179582. PMID: 37214266.
- [8] Sadat M, Abdul Hameed M, Amin N, Sherwani R. Uterine adenocarcinoma with sarcomatous overgrowth and heterologous elements: a rare case report. *J Clin Diagn Res*. 2022 Jan;16(1):ED01-ED02. PMID: 35083260.
- [9] Nishio S, Takeuchi S, Kato T, Yamada K, Matsuo T, Asami T, et al. A case of uterine adenocarcinoma treated with surgery, chemotherapy, and radiation therapy. *Gan To Kagaku Ryoho*. 2023 Sep;50(9):1093-5. PMID: 37592402..

..