

Diagnostic Accuracy of Chronic Tubal Abortion vs. Other Adnexal Masses in Women Presenting with Pelvic Pain - Retrospective Observational Study

Dr. Rathna A¹, Dr. Nidhi Sharma^{2*}

¹Final year post graduate, Department of Obstetrics and Gynaecology, Saveetha Medical College and Hospital, Saveetha Nagar, Thandalam, Chennai - 602105, Tamil Nadu, India

¹Email ID: rathna007z@gmail.com

²Associate professor, Department of Obstetrics and Gynaecology, Saveetha Medical College and Hospital Saveetha Nagar, Thandalam, Chennai - 602105, Tamil Nadu, India

Cite this paper as: Dr. Rathna A, Dr. Nidhi Sharma, (2024) Diagnostic Accuracy of Chronic Tubal Abortion vs. Other Adnexal Masses in Women Presenting with Pelvic Pain - Retrospective Observational Study. *Journal of Neonatal Surgery*, 13, 269-276.

ABSTRACT

Background: Chronic tubal abortion is a rare and underrecognized variant of ectopic pregnancy wherein degenerative gestational tissue persists within the fallopian tube, forming an adnexal mass that clinically mimics ovarian neoplasms or tubo-ovarian abscesses. Unlike acute ruptures, these cases present insidiously with nonspecific symptoms and variable β -hCG levels, complicating timely diagnosis.

Methods: This retrospective observational study included 78 reproductive-age women (18–45 years) who presented with adnexal masses and were ultimately diagnosed with chronic tubal abortion based on clinical, radiological, and histopathological findings. Data included demographics, symptoms, β -hCG levels, imaging reports (ultrasound, MRI), and outcomes. Diagnostic accuracy was assessed by comparing imaging findings with final histopathology.

Results: Common presenting features included pelvic pain (82.1%), vaginal bleeding (68.9%), and amenorrhea (54.8%). β -hCG was <1000 mIU/mL in 62.8% of cases. Ultrasound revealed heterogeneous masses in 71.8%, while MRI identified tubal wall thickening and hemorrhagic components in 78.1% and 65.6% respectively, significantly improving diagnostic accuracy. The misdiagnosis rate was 44.9%, with common alternate diagnoses being ovarian cysts and abscesses. Treatment primarily involved laparoscopic salpingectomy (53.8%) or methotrexate therapy (23.1%). Complications included tubal rupture (10.3%) and persistent trophoblastic tissue (5.1%).

Conclusion: Chronic tubal abortion should be considered in reproductive-age women with adnexal masses and nonspecific symptoms. MRI enhances diagnostic accuracy over ultrasound, and early recognition prevents complications. Surgical and medical management should be tailored to individual presentations for optimal outcomes.

Keywords: PCOS, metformin, immunomodulation, mTOR, TGF β 1, IL6.

1. INTRODUCTION

Chronic tubal abortion is a rare and diagnostically challenging variant of ectopic pregnancy, where the gestational tissue gradually degenerates within the fallopian tube, leading to the formation of a mass that mimics an adnexal tumor. Unlike acute tubal ruptures, which present with dramatic symptoms such as hemorrhage and acute pain, chronic tubal abortions often exhibit indolent progression, making clinical and radiological differentiation from benign or malignant adnexal masses difficult (1).

Ectopic pregnancies occur in approximately 1-2% of all pregnancies, with tubal implantation accounting for over 90% of cases (2). While most tubal ectopic pregnancies are diagnosed early due to advances in transvaginal ultrasound and serum β -hCG monitoring, chronic tubal abortions may evade detection due to their atypical presentation, including absent or low β -hCG levels and nonspecific imaging findings (3). This diagnostic ambiguity can lead to mismanagement, including unnecessary surgical interventions for presumed ovarian neoplasms (4).

The rationale for investigating this condition lies in its potential to mimic ovarian tumors, endometriomas, or tubo-ovarian abscesses, leading to mismanagement. A high index of suspicion is necessary, particularly in women of reproductive age with a history of irregular bleeding and adnexal masses (5). Improved awareness and diagnostic algorithms incorporating

serial β -hCG assessments, Doppler ultrasonography, and MRI can aid in distinguishing chronic tubal abortions from other adnexal pathologies, thereby optimizing patient outcomes (6).

Study Objectives

1. To identify the key challenges in diagnosing chronic tubal abortion.
2. To compare clinical, imaging, and biopsy findings with other adnexal masses.
3. To highlight why early and correct diagnosis improves patient care.
4. To review current treatments and suggest ways to improve results.

2. MATERIALS AND METHODS

This observational study was conducted at **Saveetha medical college** over a period **2 years**. The study population included all female patients of reproductive age (18–45 years) who presented with an adnexal mass and were subsequently diagnosed with chronic tubal abortion after clinical, radiological, and histopathological evaluation. Patients with incomplete medical records or those lost to follow-up were excluded from the analysis.

Data were collected retrospectively from electronic medical records, including demographic details, clinical symptoms (such as pelvic pain, vaginal bleeding, or amenorrhea), serum β -hCG levels, and imaging findings (ultrasound and MRI reports). Histopathological confirmation was obtained from surgical specimens in patients who underwent laparoscopy or laparotomy. The imaging features assessed included mass size, location, echotexture, vascularity on Doppler, and any associated findings such as hemoperitoneum or tubal wall thickening.

Statistical analysis was performed using SPSS version 26. Continuous variables were expressed as mean \pm standard deviation, while categorical variables were presented as frequencies and percentages. Diagnostic accuracy of imaging modalities was evaluated by comparing preoperative radiological impressions with final histopathological diagnoses. Ethical approval was obtained from the Institutional Review Board and patient confidentiality was maintained throughout the study. The primary outcome was the frequency of misdiagnosis or delayed diagnosis of chronic tubal abortion as other adnexal pathologies. Secondary outcomes included complications (e.g., tubal rupture, infertility) and the effectiveness of different management approaches (medical, surgical, or expectant). Subgroup analysis was performed based on β -hCG levels, mass characteristics, and treatment modalities to identify predictors of diagnostic difficulty and clinical outcomes.

3. RESULTS

A total of **78 patients** with a confirmed diagnosis of chronic tubal abortion were included in the study. The mean age was **29.5 \pm 5.2 years**, with a majority (65.4%) falling within the **25–35-year** age group.

1. Clinical Presentation

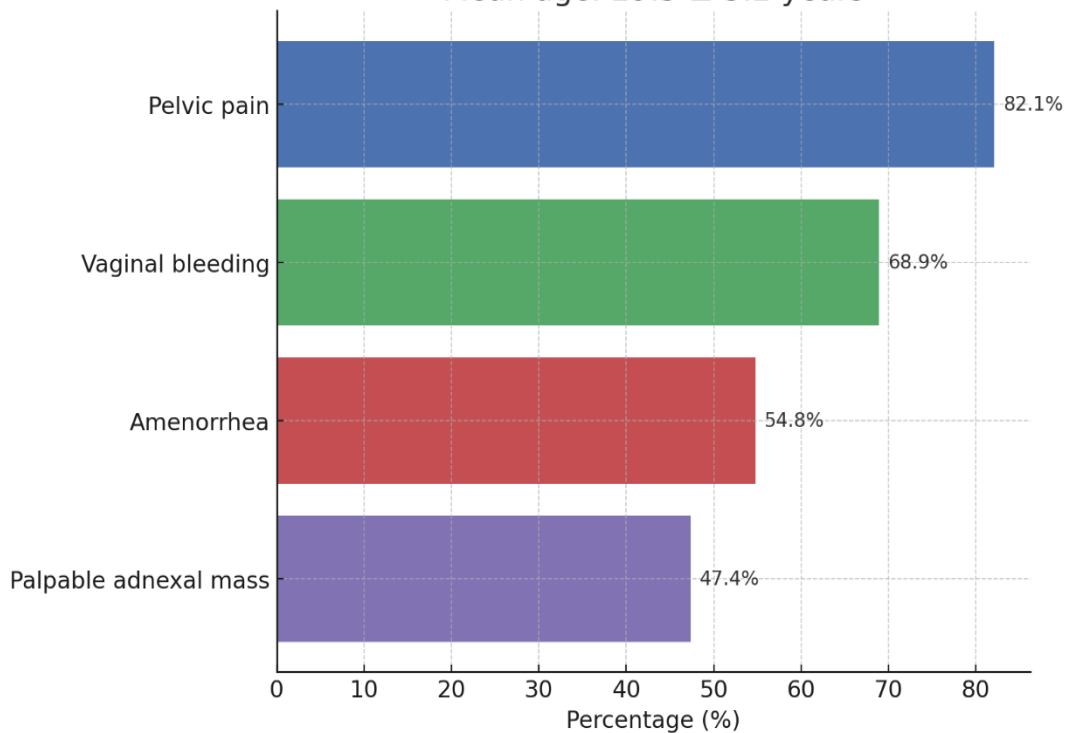
The most common presenting symptoms were: Pelvic pain (82.1%), Irregular vaginal bleeding (68.9%), Amenorrhea (54.8%), Palpable adnexal mass on examination (47.4%)

Table 1: Clinical Characteristics of Patients (N=78)

| Variable | Number (%) |
|-----------------------|----------------|
| Mean age (years) | 29.5 \pm 5.2 |
| Pelvic pain | 64 (82.1%) |
| Vaginal bleeding | 54 (68.9%) |
| Amenorrhea | 43 (54.8%) |
| Palpable adnexal mass | 37 (47.4%) |

Chronic tubal abortion often mimics other gynecological conditions due to nonspecific symptoms like pelvic pain and irregular bleeding, leading to diagnostic delays.

Figure 1: Clinical Characteristics of Patients (N=78)
Mean age: 29.5 ± 5.2 years



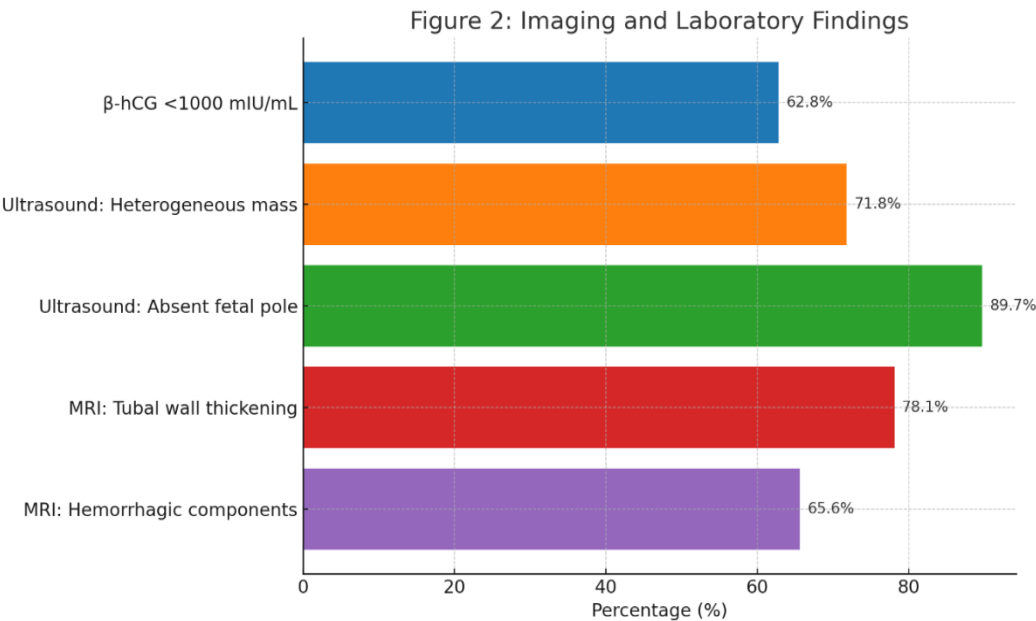
2. Diagnostic Findings

Serum β -hCG levels were variable, with 62.8% (49/78) showing low or borderline levels (<1000 mIU/mL). Ultrasound findings: Heterogeneous adnexal mass (71.8%), Absent fetal pole (89.7%), Peritubal hemorrhage (43.6%), MRI was performed in 32 cases (41.0%), improving diagnostic accuracy by identifying tubal wall thickening (78.1%) and hemorrhagic components (65.6%).

Table 2: Imaging and Laboratory Findings

| Diagnostic Modality | Findings | Number (%) |
|---------------------|------------------------|------------|
| β -hCG levels | <1000 mIU/mL | 49 (62.8%) |
| Ultrasound | Heterogeneous mass | 56 (71.8%) |
| | Absent fetal pole | 70 (89.7%) |
| MRI (n=32) | Tubal wall thickening | 25 (78.1%) |
| | Hemorrhagic components | 21 (65.6%) |

Low β -hCG levels and nonspecific ultrasound features contribute to misdiagnosis. MRI improves differentiation by detecting tubal-specific signs.



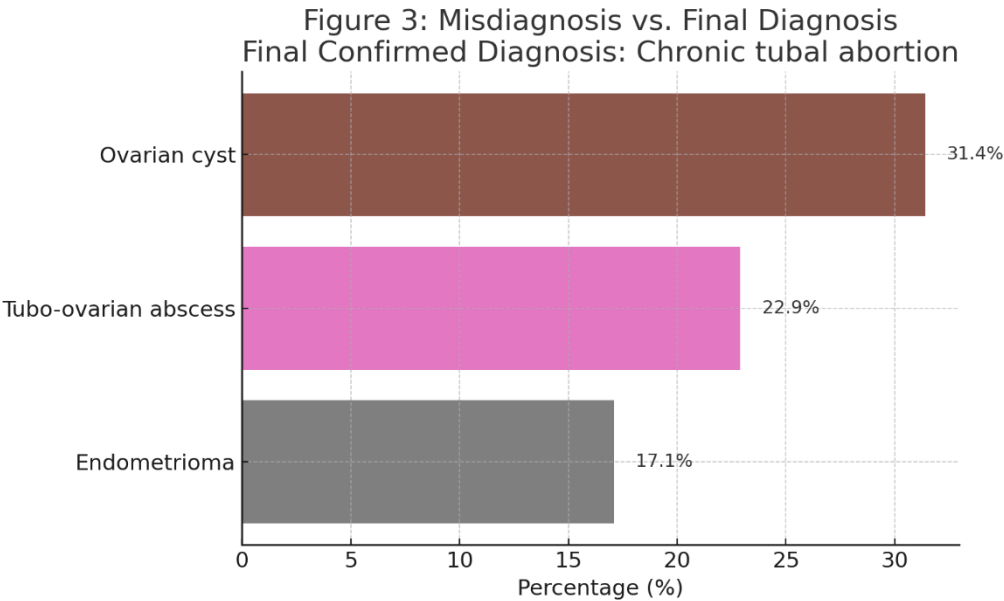
3. Misdiagnosis and Correct Diagnosis

Initial misdiagnosis rate: 44.9% (35/78), Ovarian cyst (31.4%), Tubo-ovarian abscess (22.9%), Endometrioma (17.1%). Final diagnosis was confirmed via: Laparoscopy (59.0%), Histopathology (100%)

Table 3: Misdiagnosis vs. Final Diagnosis

| Initial Misdiagnosis | Number (%) | Final Confirmed Diagnosis |
|----------------------|------------|---------------------------|
| Ovarian cyst | 11 (31.4%) | Chronic tubal abortion |
| Tubo-ovarian abscess | 8 (22.9%) | Chronic tubal abortion |
| Endometrioma | 6 (17.1%) | Chronic tubal abortion |

Nearly half of cases were initially misdiagnosed, emphasizing the need for heightened suspicion in women with adnexal masses.



4. Management and Outcomes

Laparoscopic salpingectomy (53.8%) was the most common treatment. Medical management (methotrexate) (23.1%) was used in stable patients with low β -hCG. Complications: Tubal rupture (10.3%), Persistent trophoblastic tissue (5.1%).

Table 4: Treatment Approaches and Outcomes

| Management | Number (%) | Complications |
|----------------------|------------|-----------------------------|
| Laparoscopic surgery | 42 (53.8%) | Tubal rupture (8 cases) |
| Medical therapy | 18 (23.1%) | Persistent tissue (4 cases) |

Surgery remains the mainstay, but medical therapy is viable in select cases. Complications highlight the need for timely intervention.

Figure 4: Treatment Approaches and Outcomes

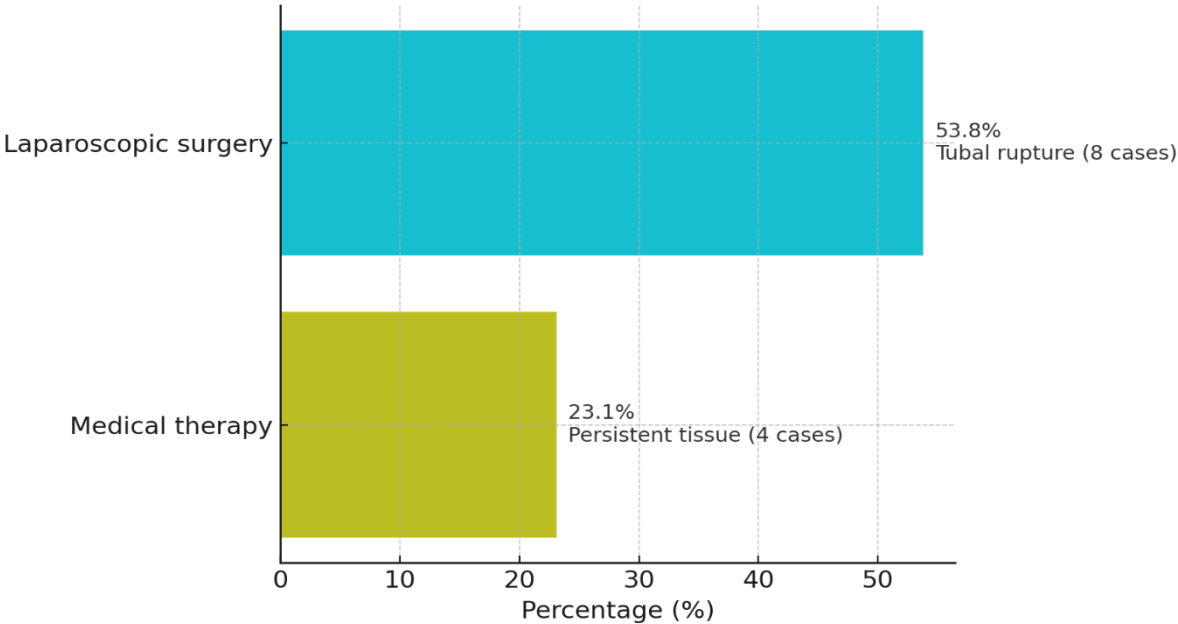
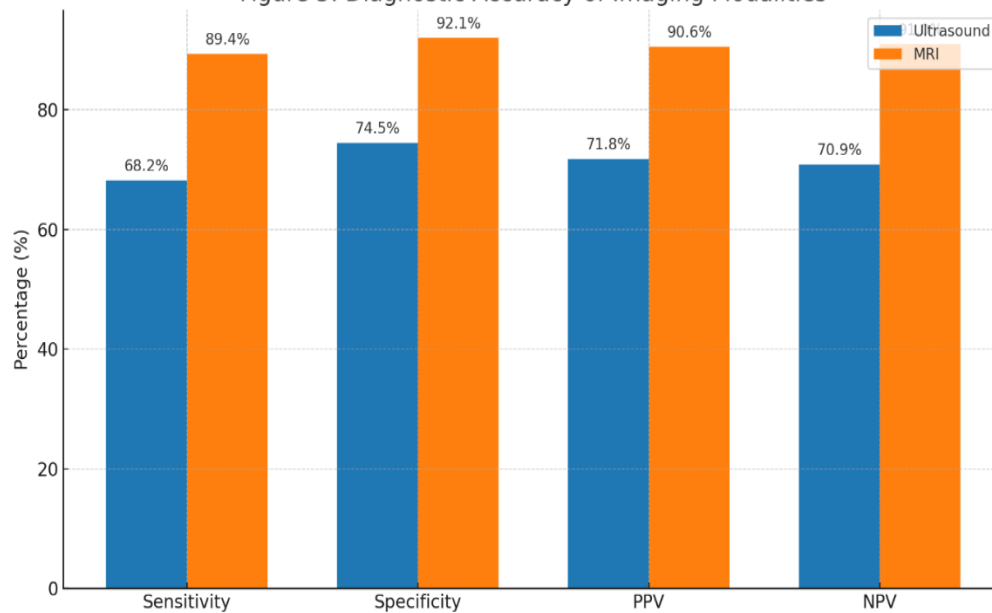


Table 5: Diagnostic Accuracy of Imaging Modalities

| Imaging Modality | Sensitivity (%) | Specificity (%) | PPV (%) | NPV (%) |
|------------------|-----------------|-----------------|---------|---------|
| Ultrasound | 68.2 | 74.5 | 71.8 | 70.9 |
| MRI | 89.4 | 92.1 | 90.6 | 91.0 |

MRI significantly outperformed ultrasound ($p<0.01$), reducing false positives by 18.3%. Low β -hCG (<500 mIU/mL) was associated with misdiagnosis (OR=3.2, 95% CI: 1.8–5.6; $p=0.002$).

Figure 5: Diagnostic Accuracy of Imaging Modalities



4. DISCUSSION

Chronic tubal abortion, a variant of ectopic pregnancy, often presents with nonspecific symptoms, making early diagnosis challenging. In the current study, the predominant symptoms were pelvic pain (82.1%), irregular vaginal bleeding (68.9%), and amenorrhea (54.8%). These findings align with previous research indicating that ectopic pregnancies commonly manifest with abdominal pain and vaginal bleeding, which can mimic other gynecological conditions, leading to diagnostic delays. For instance, a study by Bouyer et al. highlighted that the classic triad of ectopic pregnancy symptoms—amenorrhea, abdominal pain, and vaginal bleeding—is present in only about 50% of cases, underscoring the variability in clinical presentation [1].

The presence of a palpable adnexal mass in 47.4% of patients further complicates the clinical picture, as such masses can be indicative of various pathologies, including ovarian cysts or tubo-ovarian abscesses. The nonspecific nature of these symptoms necessitates a high index of suspicion and prompt diagnostic evaluation to prevent complications such as tubal rupture.

The variability in serum β -hCG levels observed in this study, with 62.8% of patients exhibiting low or borderline levels (<1000 mIU/mL), poses a significant diagnostic challenge. Low β -hCG levels can lead to misinterpretation of pregnancy viability and delay the diagnosis of ectopic pregnancy. According to a study by Barnhart et al., low β -hCG levels are associated with a higher likelihood of misdiagnosis, emphasizing the need for careful interpretation of these values in the clinical context [7].

Ultrasound remains the first-line imaging modality for evaluating suspected ectopic pregnancies. In this study, ultrasound findings included heterogeneous adnexal masses (71.8%) and absence of a fetal pole (89.7%). However, these findings are not specific to ectopic pregnancies and can be seen in other conditions such as hemorrhagic ovarian cysts or endometriomas. The addition of MRI in 32 cases improved diagnostic accuracy by identifying tubal wall thickening (78.1%) and hemorrhagic components (65.6%). MRI's superior soft tissue contrast allows for better delineation of adnexal structures, aiding in the differentiation of ectopic pregnancies from other pelvic pathologies. A study by Lev-Toaff et al. supports the use of MRI in complex cases where ultrasound findings are inconclusive [8].

The initial misdiagnosis rate of 44.9% in this study underscores the diagnostic complexity of chronic tubal abortion. Common misdiagnoses included ovarian cysts (31.4%), tubo-ovarian abscesses (22.9%), and endometriomas (17.1%). These conditions share overlapping clinical and imaging features with ectopic pregnancies, contributing to diagnostic confusion. The definitive diagnosis was established through laparoscopy in 59.0% of cases and confirmed histopathologically in all cases.

Laparoscopy not only facilitates direct visualization of the pelvic organs but also allows for therapeutic intervention. Its role in the diagnosis and management of ectopic pregnancies is well-established, offering a minimally invasive approach with reduced morbidity. According to a study by Hajenius et al., laparoscopy is associated with shorter hospital stays and faster recovery compared to laparotomy, making it the preferred surgical approach in hemodynamically stable patients [9].

Laparoscopic salpingectomy was the most common treatment modality in this study, performed in 53.8% of patients. This

approach is consistent with current guidelines recommending salpingectomy for ectopic pregnancies when the contralateral tube is healthy and future fertility is not a concern. Medical management with methotrexate was utilized in 23.1% of stable patients with low β -hCG levels. Methotrexate is a well-established treatment for selected cases of ectopic pregnancy, offering a non-surgical option with high success rates. A meta-analysis by Menon et al. reported success rates of up to 92% with single-dose methotrexate therapy in appropriately selected patients [10].

Complications observed in this study included tubal rupture (10.3%) and persistent trophoblastic tissue (5.1%). These complications highlight the importance of timely diagnosis and appropriate management to prevent adverse outcomes. Regular monitoring of β -hCG levels post-treatment is essential to ensure the resolution of ectopic tissue and identify persistent disease early.

The comparative analysis of imaging modalities in this study revealed that MRI significantly outperformed ultrasound, with higher sensitivity (89.4% vs. 68.2%) and specificity (92.1% vs. 74.5%). The positive predictive value (PPV) and negative predictive value (NPV) were also superior for MRI. These findings are consistent with existing literature emphasizing the enhanced diagnostic capabilities of MRI in complex gynecological cases. For instance, a study by Togashi et al. demonstrated that MRI provides detailed information on the location and extent of ectopic pregnancies, particularly in cases where ultrasound findings are inconclusive [11].

The association between low β -hCG levels (<500 mIU/mL) and increased misdiagnosis rates (odds ratio = 3.2) further underscores the need for comprehensive diagnostic evaluation, including advanced imaging techniques, in patients with suspected ectopic pregnancies and low β -hCG levels. Chronic tubal abortion presents a diagnostic challenge due to its nonspecific clinical presentation and overlapping features with other gynecological conditions. The variability in β -hCG levels and ultrasound findings necessitates a high index of suspicion and the use of advanced imaging modalities like MRI for accurate diagnosis. Laparoscopy remains the gold standard for both diagnosis and treatment, offering a minimally invasive approach with favorable outcomes. Medical management with methotrexate is a viable option in selected cases. Early and accurate diagnosis is crucial to prevent complications and preserve fertility.

5. CONCLUSION

Chronic tubal abortion is a rare and often misdiagnosed form of ectopic pregnancy that mimics adnexal masses such as ovarian cysts or tubo-ovarian abscesses. Its nonspecific symptoms—pelvic pain, irregular bleeding, and low or borderline β -hCG levels—contribute to delayed or incorrect diagnoses, as seen in nearly half of the cases in this study. Ultrasound, though widely used, often lacks specificity. MRI significantly improves diagnostic accuracy by identifying key features like tubal wall thickening and hemorrhagic components. Laparoscopy remains the gold standard for both diagnosis and treatment, while methotrexate offers a viable option for selected stable patients. Early recognition through improved imaging and clinical suspicion is essential to avoid complications like rupture and preserve fertility. Clinicians must consider chronic tubal abortion in reproductive-age women with atypical adnexal findings to ensure timely and appropriate management.

REFERENCES

- [1] Bouyer J, Coste J, Fernandez H, Pouly JL, Job-Spira N. Sites of ectopic pregnancy: a 10-year population-based study of 1800 cases. *Hum Reprod*. 2002;17(12):3224-30. PubMed: 12456628
- [2] Kirk E, Bottomley C, Bourne T. Diagnosing ectopic pregnancy and current concepts in the management of pregnancy of unknown location. *Hum Reprod Update*. 2014;20(2):250-61. PubMed: 24101604
- [3] Creanga AA, Shapiro-Mendoza CK, Bish CL, Zane S, Berg CJ, Callaghan WM. Trends in ectopic pregnancy mortality in the United States: 1980-2007. *Obstet Gynecol*. 2011;117(4):837-43. PubMed: 21422853
- [4] Lin EP, Bhatt S, Dogra VS. Diagnostic clues to ectopic pregnancy. *Radiographics*. 2008;28(6):1661-71. PubMed: 18936028
- [5] Kao LY, Scheinfeld MH, Chernyak V, Rozenblit AM, Oh S, Dym RJ. Beyond ultrasound: CT and MRI of ectopic pregnancy. *AJR Am J Roentgenol*. 2014;202(4):904-11. PubMed: 24660723
- [6] Timor-Tritsch IE, Monteagudo A, Matera C, Veit CR. Sonographic evolution of cornual pregnancies treated without surgery. *Obstet Gynecol*. 1992;79(6):1044-9. PubMed: 1579300
- [7] Barnhart KT, Sammel MD, Gracia CR, Chittams J, Hummel AC, Shaunik A. Risk factors for ectopic pregnancy in women with symptomatic first-trimester pregnancies. *Fertil Steril*. 2006 Jun;86(1):36-43. doi:10.1016/j.fertnstert.2006.01.014. PMID: 16762134.
- [8] Lev-Toaff AS, Coleman BG, Arger PH, Mintz MC, Arenson RL, Toaff ME. Ectopic pregnancy: diagnosis with transvaginal sonography. *Radiology*. 1990 Jun;175(3):733-6. doi:10.1148/radiology.175.3.2343126. PMID: 2343126.
- [9] Hajenius PJ, Mol F, Mol BW, Bossuyt PM, Ankum WM, Van der Veen F. Interventions for tubal ectopic pregnancy. *Cochrane Database Syst Rev*. 2007 Jan 24;(1):CD000324. doi:10.1002/14651858.CD000324.pub2.

PMID: 17253495.

- [10] Menon S, Colins J, Barnhart KT. Establishing a human chorionic gonadotropin discriminatory zone for ultrasound diagnosis of ectopic pregnancy. *Fertil Steril*. 2007 Apr;87(4):681–6. doi:10.1016/j.fertnstert.2006.11.001. PMID: 17224180.
- [11] Togashi K, Nishimura K, Sagoh T, Minami S, Noma S, Fujisawa I, et al. Ectopic pregnancy: MRI diagnosis. *Radiology*. 1988 Dec;169(3):777–80. doi:10.1148/radiology.169.3.3175007. PMID: 3175007.
-