

## Phytochemical And Pharmacological Evaluation Of *Martynia Annua* Linn. And *Tephrosia Purpurea* Linn. For Anti-Inflammatory And Anti-Hemorrhoidal Effects In Rats

Anoop Singh<sup>1</sup>, Om Prakash Agrawal<sup>2</sup>

<sup>1,2</sup>Bhabha University, Jatkhedi, NH-12, Narmadapuram Road, Bhopal, Madhya Pradesh Pin-462026

**Cite this paper as:** Anoop Singh, Om Prakash Agrawal, (2025) Phytochemical And Pharmacological Evaluation Of *Martynia Annua* Linn. And *Tephrosia Purpurea* Linn. For Anti-Inflammatory And Anti-Hemorrhoidal Effects In Rats. *Journal of Neonatal Surgery*, 14 (32s), 1459-1472.

### ABSTRACT

The present study is aimed to study the anti-inflammatory and anti-hemorrhoidal effect of *Martynia annua* and *Tephrosia purpurea* extracts in rats. Aerial parts of *Tephrosia purpurea* and leaves of *Martynia annua* were selected for extraction with petroleum ether and ethanol. Flavonoid-rich extracts were tested for anti-inflammatory and anti-hemorrhoidal activities (200 and 300 mg/kg bwt.). The anti-inflammatory effect was investigated on Carrageenan and histamine-induced paw edema models by measuring percent inhibition of paw edema at different time intervals. The anti-hemorrhoidal activity was studied by using croton oil-induced hemorrhoid on rats. Effect was assessed by measuring pro-inflammatory mediators in blood, Severity score and Recto Anal Co-efficient and antioxidants level in rectoanal tissues of rats. Results of the study indicate that flavonoid-rich extract of *Tephrosia purpurea* and *Martynia annua* significantly inhibited edema in a dose-dependent manner with the treatment of 200 and 300 mg/kg b.wt p.o. in both methods. Both extracts are significantly able to restore pro-inflammatory mediators (TNF- $\alpha$ , IL-6 and PGE2) near normal level. Both, flavonoid-rich extracts treated group also maintained Severity score and rectoanal coefficient ( $0.268 \pm 0.08$  and  $0.405 \pm 0.11$ ) near to the normal control group of animals. MDA level was found statistically significant ( $p < 0.001$ ) decreased after five days of treatment. The tissue antioxidant level is very close to the normal level after treatment with both flavonoid-rich extracts. The present study concluded that the anti-inflammatory and anti-hemorrhoidal effect of flavonoid-rich extracts of *Martynia annua* and *Tephrosia purpurea* could be due to the presence of major flavonoid components, namely quercetin and luteolin in both plants.

**Keywords:** Anti-inflammatory, Antihemorrhoid, Carrageenan, *Martynia annua*, Pro-inflammatory, *Tephrosia purpurea*.

### 1. INTRODUCTION

Hemorrhoids are a common anorectal disorder characterized by masses of tissues in the anal region which consists of blood vessels, supporting tissues, muscle, and elastic fibres. The incidence of hemorrhoids can occur in any age but its prevalence is high at 45–65 years age. Hemorrhoids are symptomized by inflammation reaction and vascular hyperplasia. During hemorrhoids, abnormal dilatation, distortion of vascular channel, and destruction in the supporting tissues occur. Several factors contribute to hemorrhoids development, but constipation and prolonged straining are the most important.[1] Rectal bleeding, mucous discharge, perianal pain, irritation and perianal itching are the common symptoms of hemorrhoids. Internal hemorrhoids cannot cause cutaneous pain, because they are above the dentate line and are not innervated by cutaneous nerves. However, they can bleed, prolapse, and, as a result of the deposition of an irritant onto the sensitive perianal skin, cause perianal itching and irritation. Internal hemorrhoids can produce perianal pain by prolapsing and causing spasm of the sphincter complex around the hemorrhoids. This spasm results in discomfort while the prolapsed hemorrhoids are exposed. This muscle discomfort is relieved with reduction.[2] *Tephrosia purpurea* (Linn.) Pers. (Fabaceae) is commonly known as Sarpunkha. It is a deep-rooted bush-like perennial herb, up to 60–90 cm high, remaining green throughout the dry season. It is an important component of herbal preparation such as Tephroli and Yakrifit used for liver disorders.[3] Decoction of roots is given in dyspepsia, diarrhea, rheumatism, asthma and urinary disorder. Decoction of pods is used as vermifuge and to stop vomiting. Seeds oil is specific against scabies, itch, eczema and other skin eruptions.[4] In ayurvedic practice, the plant is digestive, antiulcer, diuretic, and antitussive. It has undergone clinical trial in viral hepatitis and improves liver function. The plant is also effective in bilious febrile attacks, boils, pimples, bleeding piles, and obstruction of liver and spleen.[5,6]

The roots, leaves and seeds contain tephrosin, rutin, deguelin, and quercetin. The roots also contain isotephrosin and rotenone. Rotenoids are produced in in-vitro tissue cultures of the plant parts. Purpurin, a flavonone has been isolated from the seeds, as also 8-substituted flavonoid and 3-substituted oxygenated chalcones.[7]

*Martynia annua* Linn. (Family Martyniaceae), a glandular hairy annual herb and commonly known as Bichchhu. It is an herbaceous erect, branched, glandular- hairy annual. Leaves opposite, broadly ovate to deltoid, base cordate, apex acute, margins repand-dentate. Flowers large, foxglove shaped, pink and dark-purple blotched with yellow inside, borne in 10-20 flowered racemes. Fruits are hard, woody with 2-sharp recurved hooks and seeds oblong.[5] The leaves contain chlorogenic acid, seeds- 10.35% of pale yellow semi-drying oil and fatty acids (palmitic acid, stearic acid, oleic acid and arachidic acid). The leaves are eaten in times of scarcity. They are repeated in epilepsy and applied to tuberculosis gland of the neck. The juice is used as gargle for soar throat. The fruit is considered alexiteric and useful in inflammation, scabies, painful urination.[8] The anti-inflammatory activity of ethanol extract of *Martynia diandra* Glox. was reported in both acute and sub-acute inflammatory process.[9]

## 2. MATERIAL AND METHODS

### Collection and Identification of Plant Materials

The aerial part of *Tephrosia purpurea* Linn. was collected from February to March from the roadside of the campus of RKDF University Bhopal (M.P.). The leaves of *Martynia annua* Linn. was collected in September to October around the campus of RKDF University Bhopal (M.P.). *Tephrosia purpurea* Linn. and *Martynia annua* Linn. were identified and authenticated in the Department of Botany, Barkatullah University, Bhopal (M.P.). The plant materials were dried in shade, powdered moderately and pass through sieve No. 10. The powdered plant material (100 gm) of *Tephrosia purpurea* Linn. and *Martynia annua* Linn. (100 gm) were defatted with petroleum ether (60–80°C), and extracted with ethyl alcohol (95%) in a soxhlet apparatus. Ethanol extract was used for further study.

### Preparation of Flavonoid-rich Extract of *Tephrosia purpurea* Linn.

The powdered plant materials *Tephrosia purpurea* Linn. (aerial parts) was extracted with petroleum ether (60– 80°C) in a soxhlet apparatus for three days up to complete defatting. The defatted dried powdered material was extracted with ethanol (95%) for 3-4 days. The filtrate ethanol extract was concentrated. The semisolid ethanol extract was suspended in distilled water and repeatedly extracted with ethyl acetate in a separating funnel. The removal of solvent from the ethyl acetate fraction yielded a brown powdered product (A) which gave positive tests for the presence of flavonoids. The aqueous fraction layer was dried (B) and stored for study.

### Preparation of Flavonoid-rich Extract of *Martynia annua* Linn.

The powdered plant materials *Martynia annua* Linn. leaves were extracted in a soxhlet apparatus with petroleum ether (60– 80°C) for defatting. The defatted dried powdered material was extracted with ethanol (95%) for 3–4 days. The filtrate ethanol extract was concentrated and completely dried. The dried ethanol extract was treated with chloroform repeatedly to obtain chloroform soluble fraction (A) and insoluble chloroform fraction. The insoluble chloroform fraction was dissolved in methanol repeatedly to obtain methanol insoluble (B) and methanol soluble fraction (C). The methanol soluble fraction has greater yield than methanol insoluble fraction.

### Animal Selection

Wistar rats (Male) weighing 150-180g were selected for the anti-inflammatory and anti-hemorrhoid studies and were placed in polypropylene cages in animal houses. All animals had a free access to water and ad libitum. The animals were acclimatized to standard laboratory temperature conditions ( $22 \pm 3^\circ\text{C}$ ) and maintained on 12:12 h light: dark cycle. The animal care and experimental protocols were following CPCSEA/IAEC. The animal are randomly selected, marked to permit individual identification and kept in their cages for at least 5 days prior to dosing to allow for acclimatization to the laboratory conditions.

### Acute Toxicity Study

The acute oral toxicity studies were carried out as per the Organization for Economic Co-operation and Development (OECD) guidelines, draft guidelines 423 received from Committee for Control and Supervision of Experiments on Animals (CPCSEA), Ministry of Social Justice and Empowerment, Government of India.

Wistar rats weighing 150–180g of both sexes were selected for acute toxicity study. The conventional commercial pellet available as a rodent diet and water *ad libitum* were provided to all animals. All animals were maintained standard conditions under housed individually for 7 days before starting of the experiment under a temperature- controlled ( $25 \pm 2^\circ\text{C}$ ) animal room. All experimental procedures were reviewed and verified by the Institutional Animal Ethics Committee (Reg. No. 1546/PO/E/S/11/ CPCSEA).

### Anti-inflammatory Activity

#### Animal Protocol

Wistar albino rats weighing between 150–180 gm. were selected for the anti-inflammatory studies. They will be kept in the animal house in a controlled room temperature at  $25 \pm 2^\circ\text{C}$ , relative humidity 44–56%, light and dark cycles of 10 and 14

hours, respectively for 1 week before the experiment. The animals will be grouped and housed in polyacrylic cages for the experiment. Animals had free excess to water and food. However, they fasted for 48 hours. before the operative procedure. The animals were divided into following groups containing 5 animals each group.

Group I was indicated as control and given sodium carboxymethyl cellulose (0.5 %) p.o.

Groups II, was given flavonoid-rich extract of *Tephrosia purpurea* with 200 mg/kg bwt)

Groups III, was given flavonoid-rich extract of *Tephrosia purpurea* with 300 mg/kg bwt)

Groups IV, was given flavonoid-rich extract of *Martynia annua* leaves (200 mg/kg bwt)

Groups V, was given flavonoid-rich extract of *Martynia annua* leaves with 300 mg/kg bwt)

Groups VI, was indicated as standard and given Indomethacin (10 mg/kg) p.o.

### **Preparation of Dosage Form**

The suspension of flavonoid-rich extract of *Tephrosia purpurea* and flavonoid-rich extract of *Martynia annua* leaves were prepared by mixing the accurately weighed quantity of the extract with 0.5% carboxy methyl cellulose in a beaker. Indomethacin was diluted with 0.5% carboxy methyl cellulose. The vehicle to be administered to the control group was prepared using the same procedure without adding extracts.

### **Carrageenan induced Rat Paw Edema**

The acute anti-inflammatory effect was evaluated by carrageenan-induced rat paw edema according to the reported method Amdekar *et al.* (2012).[10] Edema was induced by injecting 0.1-mL of 1% carrageenan in physiological saline into the subplantar tissues of the left hind paw of each rat. The flavonoid-rich extract of *Tephrosia purpurea* (200 and 300 mg/kg) and flavonoid-rich extract of *Martynia annua* leaves (200 and 300 mg/kg) were administered orally 30 minutes prior to carrageenan administration. The paw volume was measured at 60, 120, 180 and 240 minutes by the mercury displacement method using a plethysmograph. The percentage inhibition of paw volume in the drug-treated group was compared with the carrageenan control group. Indomethacin (10 mg/kg p.o.) was used as the standard.

Edema was calculated as percent inhibition by following equation:

$$\% \text{ edema inhibition} = [1 - (V_t / V_c)] \times 100$$

V<sub>t</sub> and V<sub>c</sub> are edema volume in the drug-treated and control groups, respectively.

### **Histamine Induced Paw Edema**

Histamine-mediated paw edema method is said to occur under chemically induced inflammation earlier in the mounting phase of the vascular reaction. In this model, swelling occurs mainly because of histamine action takes place.[11] Various inflammatory mediators, including interleukin-1 (IL-1) and P substances, usually release histamine after mast cell degranulation. This is likely to result in releasing neuropeptides, prostaglandins, and monohydroxy eicosatetraenoic acid from endothelial cells, resulting in hyperalgesia and other pro-inflammatory effects.[12]

The process was same as in case of Carrageenan- induced paw edema, except the rats were confronted by subcutaneous injection of 0.1-mL of 1% histamine solution into the subplantar side of the left hind paw instead of carrageenan. The paw volume was measured. The inflammation inhibition percentage was measured using the formula and compared to the control group.

$$\% \text{ Inhibition} = \{V_c - V_t / V_c\} \times 100$$

V<sub>t</sub> and V<sub>c</sub> edema volume in the drug treated and control groups respectively.

### **Anti-hemorrhoidal Activity**

#### **Croton-oil Induced Hemorrhoid Model**

Anti-hemorrhoidal activity of flavonoid-rich extract of *Tephrosia purpurea* and *Martynia annua* leaves was determined by the method given by Azeemuddin *et al.* (2014).[13] Wistar rats were divided into six groups: Group I marked as normal control and administered with distilled water (0.5 mL per orally) for 5 days.

Group II marked as positive control and administered with 6% croton oil, 100 µL/day into the recto-anal region for 3 days).

Group III was marked as treated group and was treated with flavonoid-rich extract of *Tephrosia purpurea* (200 mg/ kg, b.wt, PO) and 6% croton oil (100 µL/day).

Group IV was marked as treated group and was treated with flavonoid-rich extract of *Tephrosia purpurea* (300 mg/ kg, b.wt, PO) and 6% croton oil (100 µL/day).

Group V was marked as treated group and was treated with flavonoid-rich extract of *Martynia annua* leaves (200 mg/ kg,

b.wt, PO) and 6% croton oil (100 µL/day).

Group VI was marked as treated group and was treated with flavonoid-rich extract of *Martynia annua* leaves (300 mg/kg, b.wt, PO) and 6% croton oil (100 µL/day).

Group VII was marked as standard treated with Pilex granules (400 mg/kg, b.wt, PO) and 6% croton oil (100 µL/day).

Hemorrhoids were induced in all groups except normal control group by applying croton-oil preparation (deionized water, pyridine, diethyl ether, and 6% croton oil in diethyl ether in the ratio of 1: 4: 5: 10). Sterile cotton swab (4 mm in diameter) soaked in cotton oil preparation (100 µL) was inserted into the anus (about 22 mm diameter) and kept for 10 seconds.

A linear development of oedema was observed within 7–8 hours of induction of croton oil. After 24 hours of induction, relevant treatment was given to all the groups for five days. On the fifth day, 1-hour after the treatment, blood samples were collected from the retro-orbital sinus and inflammatory cytokines like PG, TNF- $\alpha$  and IL-6 were estimated in blood using Elisa Microplate Reader (Erba Lisa Scan EM, Mumbai). All animals were euthanized by exsanguinations under deep isoflurane anesthesia, and rectoanal tissue was isolated and weighed.

For histological examination, the same tissue was examined for severity score and rectoanal coefficient by fixing the tissue in 10% neutral buffered formalin. The rectoanal-coefficient (RAC) was calculated from the formula:

Rectoanal Coefficient = Weight of rectoanal tissue (mg) / Body weight (mg)

### Cytokines Assays

Blood samples were collected from the retro-orbital sinus of anesthetized rats of different groups. The serum was separated by allowing the blood to clot at room temperature for 1 hour, and then centrifuged at 2500 g for 10 minutes. Cytokines parameters such as tumor necrosis factor- $\alpha$  (TNF- $\alpha$ ), Prostaglandin E2 (PGE2), and Interlukin-6 (IL-6) were assayed in the serum samples by ELISA Reader (Erba Lisa Scan EM, Mumbai). The assays were performed according to protocol recommended by the manufacturer's (TRANSASIA, Mumbai, India).

### Assessment of Oxidative Stress Parameters

After 5th day of all treatment, the animals were killed by cervical dislocation and recto anal tissue was collected and washed in chilled sodium phosphate buffer (0.2M, pH 7). A 10% homogenate (w/v) of tissue was made in the chilled buffer using a Remi homogenizer. The unbroken cells and cell debris were removed by centrifugation at 1000 rpm for 10 min using a Remi centrifuge. Activities of different antioxidants were determined in the supernatant. The supernatant was used to estimate reduced glutathione, [14] malondialdehyde (MDA). [15] Catalase (CAT) was estimated following the breakdown of hydrogen peroxide according to the method of Beers and Sizer (1952). [16] Superoxide dismutase (SOD) was assayed according to Misra and Fridovich (1972) [17] based on the inhibition of epinephrine autoxidation by the enzyme. Reduced glutathione (GSH) content was determined by a method explained by Moron *et al.* (1979).

### Histological Studies

For histological observation, one part of the rectoanal tissue was fixed with formalin, then dehydrated in different graded alcohol (50–100%), and embedded in paraffin. Thin sections (4–5 µm) of tissue were cut and stained with staining reagents, hematoxylin and eosin (HE). [18] A light microscope was used to examine them, and photographs were collected for observation. Histological observation was taken for inflammation, congestion, hemorrhage, vasodilation and necrosis.

### Statistical Analysis

Statistical analysis of the results was done by one way analysis of variance (ANOVA) using GraphPad Prism 5 software followed by Bonferroni comparison test for significance. The results were considered statistical significance at  $p < 0.05$ .

## 3. RESULTS AND DISCUSSION

### Phytochemical Studies

The plant material *Tephrosia purpurea* Linn. (aerial parts) and *Martynia annua* Linn. (leaves) were collected and identified. The powdered materials of both plants were successively extracted with petroleum ether, chloroform, ethyl acetate, ethyl alcohol and chloroform water. The percent yields of all extracts of *Tephrosia purpurea* Linn. were found 4.5% w/w (petroleum ether), 1.6% w/w (chloroform), 3.1% w/w (ethyl acetate), 4.8% w/w (ethyl alcohol) and 2.2% w/w (chloroform water). The different extracts of *Martynia annua* Linn. were showed percent yield: 5.1% w/w (petroleum ether), 3.8% w/w (chloroform), 3.4% w/w (ethyl acetate), 4.1% w/w (ethyl alcohol) and 2.3% w/w (chloroform water).

The phytochemical analyses of all extracts were performed qualitatively for different phytoconstituents. The plant *Tephrosia purpurea* Linn. give positive test of steroids in petroleum ether and alkaloids in chloroform extract. The ethyl acetate and ethanol extract contain flavonoids, tannins, glycosides and amino acids. The aqueous extract were found the presence of carbohydrates, saponins and amino acids. In another plant *Martynia annua* Linn. petroleum ether extract containing steroids and chloroform extract were found in alkaloids. The ethyl acetate and ethanol extract contain flavonoids, tannins, and

glycosides. Aqueous extract contains carbohydrates, saponins and proteins.

### Acute Toxicity Study

Animals were under observation regularly for time duration during whole study. In all the cases no death was observed within first 24 hours. Additional observations include behavioral changes, skin color, eyes, CNS, and somatic motor behavior. Attention was also given to the observation of tremors and convulsions. No mortality or negative sign was observed up to dose of 4000 mg/kg bwt for the flavonoid-rich extract of *Tephrosia purpurea* and *Martynia annua* leaves. Therefore, the study was performed a dose selection of 200 and 300 mg/kg bwt.

### Anti-inflammatory Activity

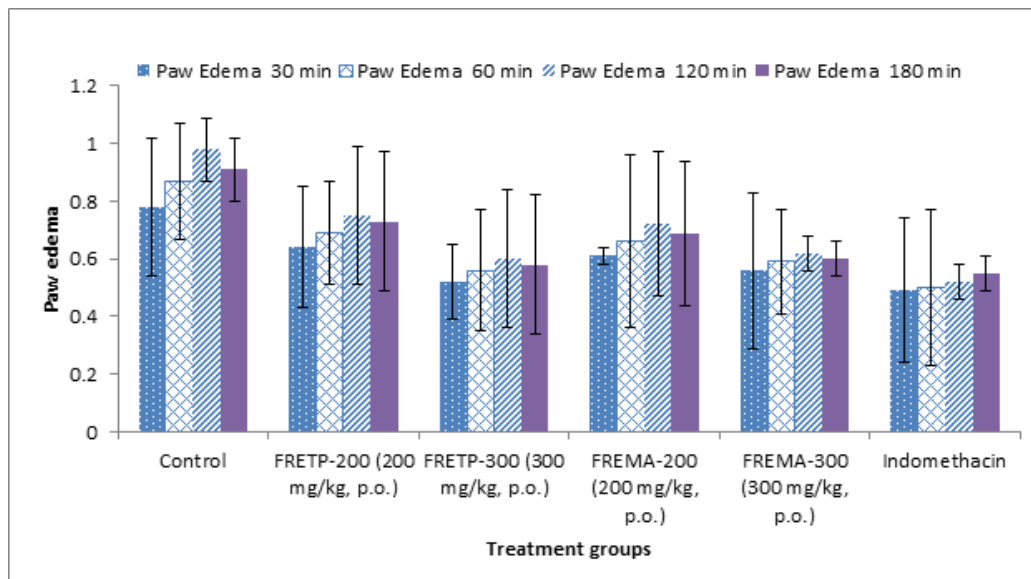
The rat paw edema increased steadily and reached its limit after 120 minutes of carrageenan injection. The flavonoid-rich extract of *Tephrosia purpurea* and *Martynia annua* were found able to reduces carrageenan-induced edema significantly ( $p < 0.05$ ) in dose-dependent manner at dose of 300 mg/kg as compared to the control group and standard, but low reduced percent at a dose of 200 mg/kg (Table 1 and Fig. 1).

Histamine is a potent vasodilator that increases blood vessel permeability. To confirm the findings of the carrageenan-induced edema test, the effect of flavonoid-rich extract of *Tephrosia purpurea* and *Martynia annua* (doses of 200 and 300 mg/kg for both) was investigated using histamine-induced edema models. Results showed that the flavonoid-rich extract of both plants substantially suppressed the edema produced by histamine at a dose of 300 mg/kg ( $p < 0.05$ ) (Table 2 and Fig. 2).

The present results were indicated that flavonoid-rich extract of *Tephrosia purpurea* and *Martynia annua* were significantly inhibited edema in dose-dependent manner with the treatment of 200 and 300 mg/kg b.wt

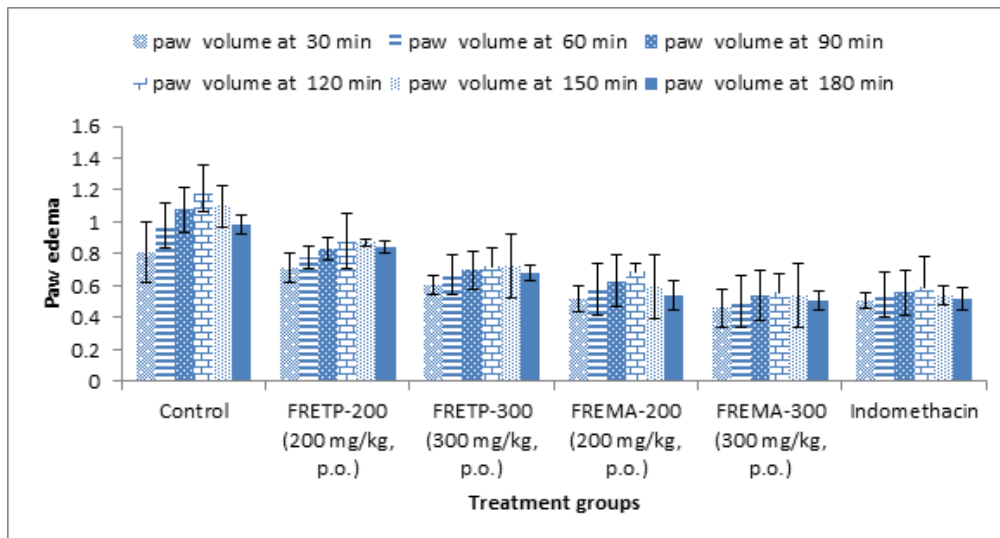
p.o. in histamine induce edema. It leads to the dilation of arterioles and venules and may increase vascular permeability.[19]

Results of the study were confirmed that flavonoid-rich extracts were capable of inhibiting edema induced by histamine. The study indicates that the extract's ability to inhibit the synthesis, release, or action of histamine involved in inflammation explains its efficacy in reducing edoema. Chronic inflammation occurs when the acute reaction is inadequate to remove the pro-inflammatory agents. Proliferation of fibroblasts and neutrophil infiltration, as well as fluid exudation both are symptoms of chronic inflammation. It is caused by the proliferation of proliferative cells that can either spread or form granulomas.[20]



**Fig. 1: Effect of flavonoid-rich extract of *Tephrosia purpurea* and *Martynia annua* leaves on Carragenan induced paw edema in rats**





**Fig. 2: Effect of flavonoid-rich extract of *Tephrosia purpurea* and *Martynia annua* on histamine-induced paw edema in rats**

**Table 1: Effect of flavonoid-rich extract of *Tephrosia purpurea* and *Martynia annua* leaves on Carrageenan induced paw edema in rats**

Carrageenan induced paw edema Mean  $\pm$  SEM (% inhibition of paw volume)

Animal groups	30 min	60 min	120 min	180 min
Control	0.78 $\pm$ 0.24	0.87 $\pm$ 0.17	0.98 $\pm$ 0.20	0.91 $\pm$ 0.31
FRETP-200 (200 mg/kg, p.o.)	0.64 $\pm$ 0.41 (17.94)	0.69 $\pm$ 0.15 (20.68)	0.75 $\pm$ 0.18 (23.46)	0.73 $\pm$ 0.24 (19.78)
FRETP-300 (300 mg/kg, p.o.)	0.52 $\pm$ 0.13 (33.34)*	0.56 $\pm$ 0.04 (35.63)*	0.60 $\pm$ 0.21 (38.77)*	0.58 $\pm$ 0.24 (36.26)*
FREMA-200 (200 mg/kg, p.o.)	0.61 $\pm$ 0.03 (21.79)	0.66 $\pm$ 0.21 (24.13)	0.72 $\pm$ 0.30 (26.53)	0.69 $\pm$ 0.25 (24.17)
FREMA-300 (300 mg/kg, p.o.)	0.56 $\pm$ 0.27 (28.20)*	0.59 $\pm$ 0.04 (32.18)*	0.62 $\pm$ 0.18 (36.73)*	0.60 $\pm$ 0.06 (34.06)*
Indomethacin	0.49 $\pm$ 0.25 (37.17)	0.50 $\pm$ 0.08 (42.52)	0.52 $\pm$ 0.27 (46.93)*	0.55 $\pm$ 0.06 (39.56)

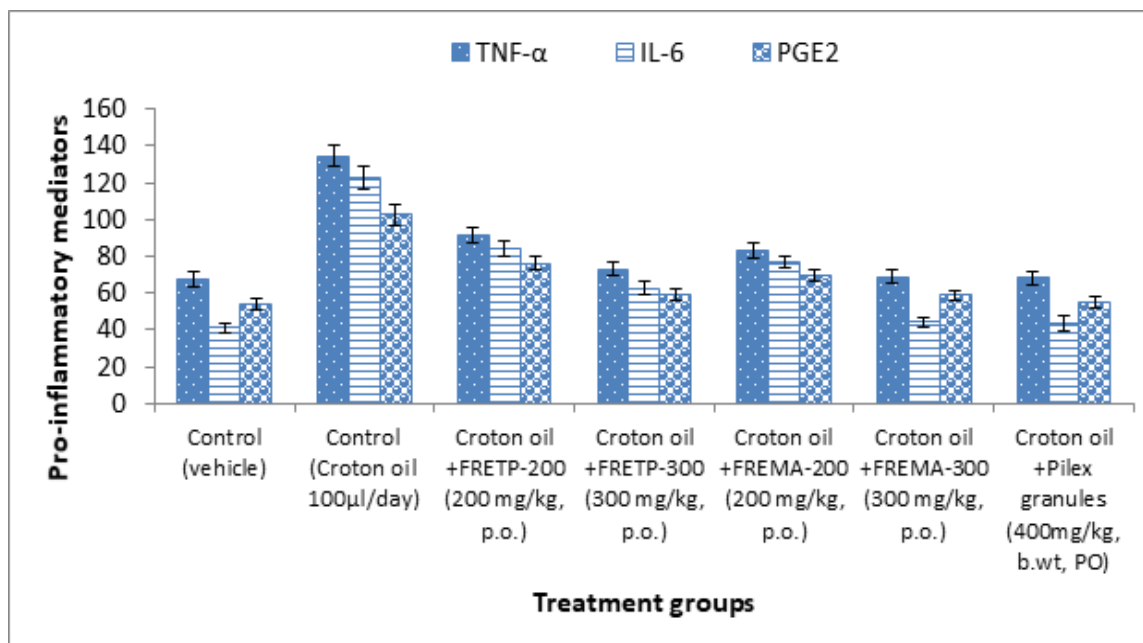
Each value is the mean  $\pm$  S.D. (n = 5), \*P < 0.01 compared with control and standard. FRETP- flavonoid-rich extract of *Tephrosia purpurea*; FREMA: flavonoid-rich extract of *Martynia annua* leaves.

**Table 2: Effect of flavonoid-rich extract of *Tephrosia purpurea* and *Martynia annua* leaves on histamine-induced paw edema in rats**

Histamine-induced paw edema Mean  $\pm$  SEM (% inhibition of paw volume)

Animal groups	30 min	60 min	90 min	120 min	150 min	180 min
Control	0.81 $\pm$ 0.19	0.98 $\pm$ 0.14	1.08 $\pm$ 0.18	1.18 $\pm$ 0.13	1.10 $\pm$ 0.017	0.98 $\pm$ 0.06
FRETP-200 (200 mg/kg, p.o.)	0.71 $\pm$ 0.09 (12.34)	0.78 $\pm$ 0.07 (20.40)	0.83 $\pm$ 0.15 (23.14)	0.90 $\pm$ 0.02 (23.72)	0.87 $\pm$ 0.06 (20.90)	0.84 $\pm$ 0.04 (14.28)
FRETP-300 (300 mg/kg, p.o.)	0.60 $\pm$ 0.08 (25.92)*	0.67 $\pm$ 0.16 (31.63)*	0.70 $\pm$ 0.06 (35.18)*	0.72 $\pm$ 0.13 (38.93)*	0.72 $\pm$ 0.07 (34.54)*	0.68 $\pm$ 0.04 (30.61)*
FREMA-200 (200 mg/kg, p.o.)	0.52 $\pm$ 0.12 (35.80)*	0.58 $\pm$ 0.11 (40.81)*	0.63 $\pm$ 0.10 (41.66)*	0.69 $\pm$ 0.20 (41.52)*	0.59 $\pm$ 0.14 (46.36)*	0.54 $\pm$ 0.09 (44.89)*
FREMA-300 (300 mg/kg, p.o.)	0.46 $\pm$ 0.12 (43.20)*	0.50 $\pm$ 0.03 (48.97)*	0.54 $\pm$ 0.04 (52.21)*	0.56 $\pm$ 0.13 (54.47)*	0.54 $\pm$ 0.04 (53.04)*	0.51 $\pm$ 0.09 (52.33)*
Indomethacin	0.51 $\pm$ 0.05 (37.03)	0.55 $\pm$ 0.09 (43.87)	0.56 $\pm$ 0.11 (48.14)	0.59 $\pm$ 0.06 (50.0)*	0.54 $\pm$ 0.08 (50.90)	0.52 $\pm$ 0.07 (46.93)

Each value is the mean  $\pm$  S.E.M. (n = 5), \*P < 0.05 compared with control and standard. FRETP- flavonoid-rich extract of *Tephrosia purpurea*; FREMA: flavonoid-rich extract of *Martynia annua*



**Fig. 3: Effect of different extracts on pro-inflammatory mediators in hemorrhoidal tissues**

### Anti-hemorrhoidal Activity

#### *Effect of Different Extracts on Pro-inflammatory Mediators in Croton Oil-induced Hemorrhoid*

Croton oil application in the rectoanal region induces hemorrhoids characterized by the marked expression of some pro-inflammatory cytokines. Inhibitory effect of flavonoid-rich extracts on the tissue level of pro-inflammatory mediators (TNF- $\alpha$ , IL-6 and PGE2) were measured in rectoanal tissues of rats by ELISA (Table 1). Results were confirmed that FRETP treatment groups were showed a significant decrease in the tissue level of pro-inflammatory mediators i.e. TNF- $\alpha$  (73.25  $\pm$  3.77), IL-6 (62.87  $\pm$  3.21), and PGE2 (59.45  $\pm$  3.10) when compared to the positive control group (134.61  $\pm$  5.75) of animals.

FREMA at 300 mg/kg has a significant effect on tissue cytokines level such as TNF- $\alpha$  ( $68.85 \pm 3.62$ ), IL-6 ( $44.37 \pm 2.85$ ), and prostaglandin E2 ( $58.73 \pm 2.34$ ). Effect of both flavonoid-rich extracts FRETP and FREMA was comparable to the standard Pilex granules treated group and approximate near to the normal control group (Table 3). Both, flavonoid-rich extracts treated group also maintained Severity score and rectoanal coefficient ( $0.268 \pm 0.08$  and  $0.405 \pm 0.11$ ) near to the normal control group of animals (Table 3 and Fig. 3).

**Table 3: Effect of different extracts on pro-inflammatory mediators in hemorrhoidal tissues**

Animal groups	TNF- $\alpha$	IL-6	PGE2
Control (vehicle)	$67.47 \pm 3.81$	$41.35 \pm 2.58$	$54.07 \pm 3.41$
Control (Croton oil 100 $\mu$ L/day)	$134.61 \pm 5.75$	$122.63 \pm 5.96$	$102.54 \pm 5.63$
Croton oil +FRETP-200 (200 mg/kg, p.o.)	$91.65 \pm 4.12$	$84.32 \pm 4.26$	$76.23 \pm 3.35$
Croton oil +FRETP-300 (300 mg/kg, p.o.)	$73.25 \pm 3.77$	$62.87 \pm 3.21$	$59.45 \pm 3.10$
Croton oil +FREMA-200 (200 mg/kg, p.o.)	$83.51 \pm 4.25$	$77.11 \pm 3.42$	$69.30 \pm 3.11$
Croton oil +FREMA-300 (300 mg/kg, p.o.)	$68.85 \pm 3.62$	$44.37 \pm 2.85$	$58.73 \pm 2.34$
Croton oil + Pilex granules (400mg/kg, b.wt, PO)	$68.12 \pm 3.91$	$43.54 \pm 3.89$	$55.07 \pm 2.81$

#### **Effect of different extracts on Severity score and Recto Anal**

##### **Co-efficient (RAC) in Croton oil-induced hemorrhoid**

All rats were scored with the Sodergren score prior to receiving a standardized treatment regime. Sodergren score is the base line of injuries before treatments. The nature and severity of the rat's hemorrhoidal symptoms have been considered as the pre-treatment baseline. A follow-up period of 5 days was carried out to study post-treatment screening to determine whether the results are pass or fail. The data was collected and compared with positive and negative control group statistically.

Results revealed no severity in normal control group and the severity score of the positive control group was found to be  $1.584 \pm 0.20$  respectively, which is statistically significant compared to the normal group. Interestingly, treatment with FRETP and FREMA (300 mg/kg) has remarkably decreased as  $0.375 \pm 0.14$  and  $0.268 \pm 0.08$ , for FRETP and FREMA, respectively. Treatment with pilex granules (400 mg/kg) has also reduced the ( $0.217 \pm 0.06$ ) rectoanal damage (Table 4 and Fig. 4).

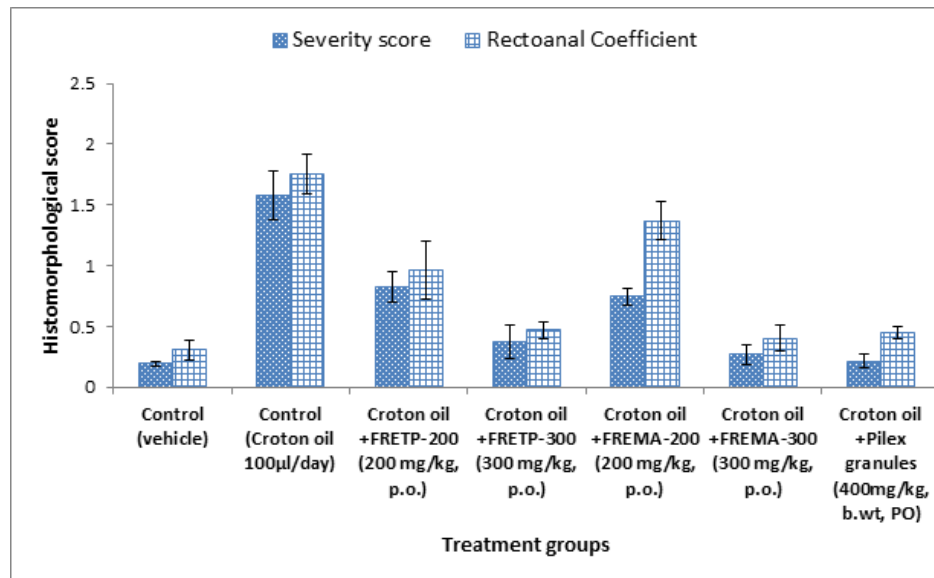
So base line for severity score has been considered zero (0) for control group and has been found out for hemorrhoid induced wistar rats 1.50 in positive group

It has been found out that severity score in hemorrhoid-induced wistar rats treated with flavonoid-rich extract of *Tephrosia purpurea* and *Martynia annua* were reduced and approximately near to the standard group treatment. This indicates that flavonoid-rich extracts of *Tephrosia purpurea* and *Martynia annua* are able to treat injuries produced due to hemorrhoids.



### Effect of different extracts on oxidative status in Croton oil induced hemorrhoid

The results of present study revealed that a significant ( $p < 0.01$ ) enhancement of malonaldehyde (MDA) level



**Fig. 4:** Effect of different extracts on Severity score and Rectoanal Coefficient of hemorrhoidal ano-rectal tissues

**Table 4:** Effect of different extracts on histomorphological score of hemorrhoidal ano-rectal tissues

Animal groups	Severity score	Rectoanal Coefficient
Control (vehicle)	0.197 ± 0.02	0.307 ± 0.08
Control (Croton oil 100 µl/day)	1.584 ± 0.20	1.752 ± 0.16
Croton oil +FRETP-200 (200 mg/kg, p.o.)	0.827 ± 0.12	0.964 ± 0.24
Croton oil +FRETP-300 (300 mg/kg, p.o.)	0.375 ± 0.14	0.473 ± 0.07
Croton oil +FREMA-200 (200 mg/kg, p.o.)	0.746 ± 0.07	1.372 ± 0.16
Croton oil +FREMA-300 (300 mg/kg, p.o.)	0.268 ± 0.08	0.405 ± 0.11
Croton oil +Pilex granules (400mg/kg, b.wt, PO)	0.217 ± 0.06	0.451 ± 0.05

in hemorrhoid induced group as compared with normal control group. This increased level was found statistically significant ( $p < 0.001$ ) decreased in hemorrhoid plus FRETP and FREMA (300 mg/kg, p.o.) treated group after five days of treatment and come back to normal control group (Fig. 5).

A rapid decline in natural antioxidant status was observed in Croton oil control group in the present study. After treatment with FRETP 200 and 300 and FREMA (200 and 300 mg/kg b.wt.) a good increase in tissue SOD activity compared with positive control group. The tissue CAT level and GSH activity ( $P < 0.01$ ) were restored to the normal significantly in the group of animals treated with FRETP and FREMA (300 mg/kg b.wt.) in dose-dependent manner as indicating antioxidant effect of flavonoid-rich extracts. The tissue antioxidant level is close to the normal level (Table 5, Figs. 5 and 6). Most of the cell and organ damage caused by free radicles comes through induced free radicals.

### Histological Observations

Histopathological examination of treated group (FRETP and FREMA, 300 mg/kg) and pilex granules (400 mg/kg) revealed that there was a marked reduction in Rectoanal Coefficient (Table 4). It is noteworthy that treatment with both FRETP and FREMA at 300 mg/kg restored almost normal architecture of recto-anal region. The histological observation of recto-anal tissue showed that partly skin and anal mucosa with normal cytoarchitecture

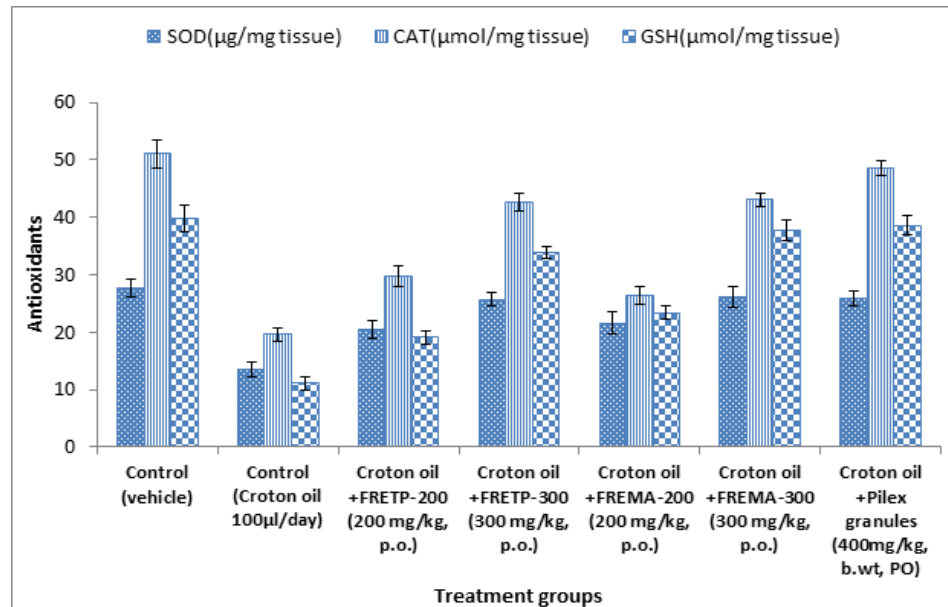


Fig. 5: Effect of different extracts on antioxidant status of hemorrhoidal rats hemorrhoidal rats

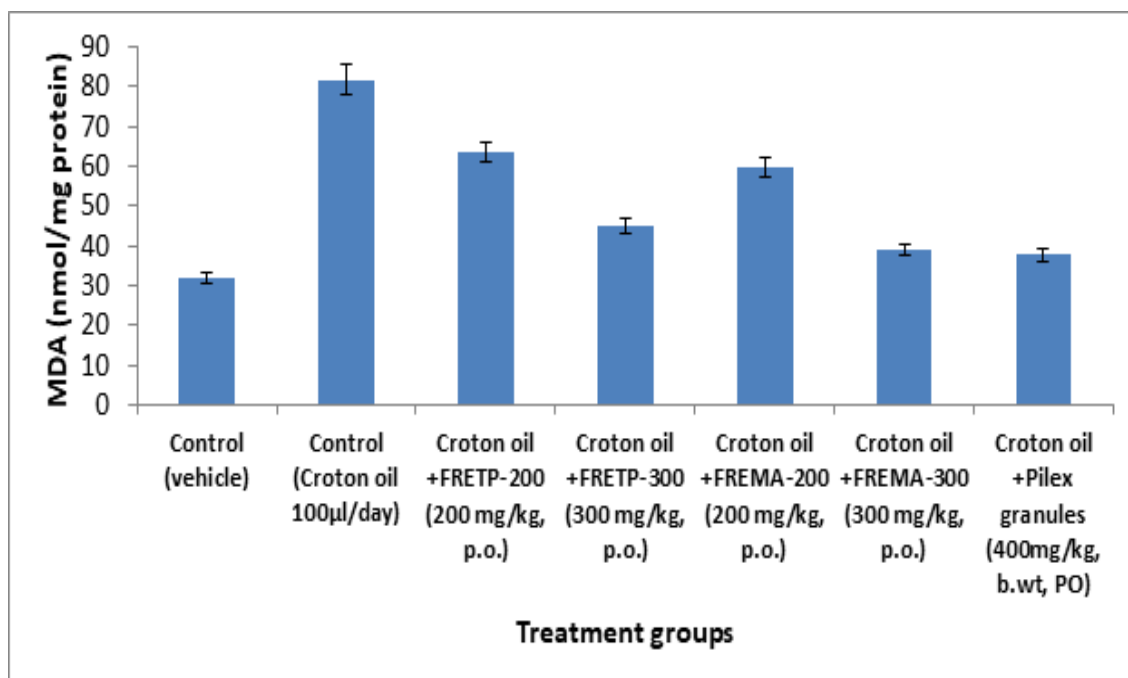
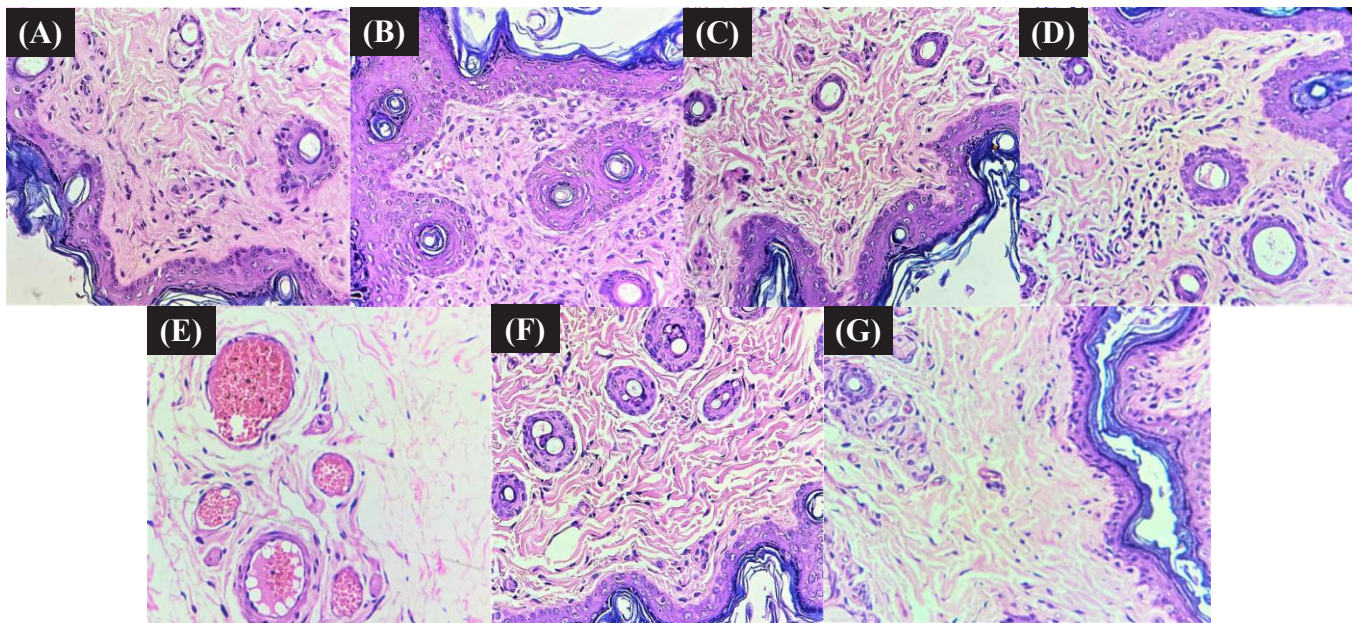


Fig. 6: Effect of different extracts on MDA level of hemorrhoidal rats

**Table 5: Effect of different extracts on antioxidant status of hemorrhoidal rats**

<i>Animal groups</i>	<i>MDA</i> (nmol/mg protein)	<i>SOD</i> ( $\mu$ g/mg tissue)	<i>CAT</i> ( $\mu$ mol/mg tissue)	<i>GSH</i> ( $\mu$ mol/mg tissue)
Control (vehicle)	31.83 $\pm$ 1.25	27.64 $\pm$ 1.52	51.12 $\pm$ 2.42	39.81 $\pm$ 2.37
Control (Croton oil 100 $\mu$ L/day)	81.65 $\pm$ 3.77	13.58 $\pm$ 1.25	19.66 $\pm$ 1.15	11.05 $\pm$ 1.05
Croton oil +FRETP-200 (200 mg/kg, p.o.)	63.47 $\pm$ 2.55	20.41 $\pm$ 1.62	29.76 $\pm$ 1.84	19.11 $\pm$ 1.18
Croton oil +FRETP-300 (300 mg/kg, p.o.)	45.28 $\pm$ 1.89	25.71 $\pm$ 1.17	42.63 $\pm$ 1.63	33.89 $\pm$ 1.02
Croton oil +FREMA-200 (200 mg/kg, p.o.)	59.79 $\pm$ 2.43	21.60 $\pm$ 1.98	26.44 $\pm$ 1.49	23.35 $\pm$ 1.12
Croton oil +FREMA-300 (300 mg/kg, p.o.)	38.93 $\pm$ 1.37	26.14 $\pm$ 1.75	43.12 $\pm$ 1.19	37.74 $\pm$ 1.85
Croton oil +Pilex granules (400mg/kg, b.wt,37.88 $\pm$ 1.65 PO)		25.82 $\pm$ 1.32	48.63 $\pm$ 1.30	38.64 $\pm$ 1.78


**Fig. 7: Photomicrograph of rectoanal tissues of different animal groups after treatment in Croton oil induced hemorrhoid in rats:**

Normal Control, (B) Disease (Croton oil 100 $\mu$ L/day), (C) Croton oil +FRETP-200 (200 mg/kg, p.o.), (D) Croton oil +FRETP-300 (300 mg/kg, p.o.), (E) Croton oil +FREMA-200 (200 mg/kg, p.o.), (F) Croton oil +FREMA-300 (300 mg/kg, p.o.), (G) Croton oil +Pilex granules(400mg/kg, b.wt, p.o.) of the recto-anal region found in control group whereas group II treated with croton oil application developed the polypoid mass of smooth muscle layer by papillary mucosa and significantly found higher inflammatory cells in the recto-anal region (Fig. 7). After treatment with FRETP and FREMA in treated group, the section showed that the inflammatory cells were observed in less dense and tissue of rectum lined found by mucosa forming luminal folds. After treatment with piles cure drug, the inflammatory cells were less seen and the section showed the normal tissue of rectum lined by mucosa forming luminal folds.

#### 4. DISCUSSION

Hemorrhoids refer to a condition in which the veins around anus or lower rectum are swollen and inflamed. In hemorrhoids there is prolapsed of the veins in the anal area due to inflammation. Therefore the treatment of this condition requires herbs that will strengthen the veins and reduce inflammation and bleeding.[21]

Carrageenan-induced paw edema is the most powerful and commonly used inflammation model for evaluation. Carrageenan is a mixture of polysaccharides derived from Irish Sea moss, *Chondrus crispus*, consisting of sulfated galactose units. Carrageenan initially releases histamine and serotonin, followed by the release of edema-producing prostaglandins, proteases and lysosomes.

Inflammation is the body's response to damage, and it is characterized by a series of events that take place in three stages. The first stage is caused by an increase in vascular permeability, which causes fluids from the blood to exude into the interstitial space; the second stage includes the penetration of blood leukocytes into the tissue, and the third stage is marked by the development of granuloma and the repair of tissue.[22] Therefore, it is important to estimate the activity of the test substance at various stages of inflammation while assessing the anti-inflammatory effect. Accordingly, flavonoid-rich extract of *Tephrosia purpurea* and *Martynia annua* were investigated for anti-inflammatory potential in Carrageenan-induced hind paw edema, and histamine-induced edema.

The paw edema caused by carrageenan in rats has been recognized as a valuable phlogistic method to investigate anti-inflammatory agents. Immediately after subcutaneous injection, severe symptoms of inflammation develop as a result of the action of pro-inflammatory agents. Edema formation is a biphasic event: the early phase (0–2.5 hours after carrageenan injection) includes the release of histamine, serotonin, and bradykinins inflammatory mediators; the late phase is associated with the release of prostaglandins (3–6 hours post-injection).[23] During the early stage of inflammation, flavonoid-rich extract and Indomethacin significantly inhibited paw edema in the present study, suggesting that the flavonoid-rich extract can block the release of histamine and serotonin within the early phase. This indicated that the flavonoid-rich extracts demonstrated their anti-inflammatory action by inhibiting histamine synthesis, release or action. The findings showed substantial anti-inflammatory activity of flavonoid-rich extracts at a 300 mg/kg dose. The results can be concluded that the significant activity may be due to the presence of flavonoids in extract of *Tephrosia purpurea* and *Martynia annua* leaves.

It is well proved that hemorrhoids are pathological conditions. In these conditions there vasodilation occurs at recto anal portion at a severe level. This promotes the inflammation of surrounding tissues, further leading to secondary difficulties. These are the extravasation of fluid into interstitial space due to increased vascular permeability and migration of many inflammatory cells (granulocytes and monocytes). In the present investigation, croton oil has been used as inducer/ phlogistic agent to induce experimental hemorrhoids. Croton oil causes severe inflammation due to the release of inflammatory lipid metabolites like (prostaglandins, leukotrienes, lipoxins) cytokines (TNF-  $\alpha$  and IL-6). These factors, alone or in combination, regulate the activation of resident cells (fibroblasts, endothelial cells, macrophages and mast cells) and newly recruited inflammatory cells (monocytes, lymphocytes, neutrophils and eosinophils), leading to the systemic response to inflammation.[24]

Severity score is one of the methods to assess the potential of damage in hemorrhoidal rats during defecation and to compare treatments, monitor disease and assist surgical decisions. This is a method for describing wistar rats with multiple injuries and evaluating emergency care. Severity score is number of injuries in recto-anal portion of wistar rats.

By producing natural antioxidants (SOD, CAT, GSH), the cell reacts to increased free radicals, reducing or removing free-radical harm to cellular structures. In particular, glutathione peroxidase catalyzes the conversion of hydroxide ions to water. SOD converts ions from superoxide to hydrogen peroxide and is then converted by catalase to oxygen and water. Superoxide dismutase occurs in various isoforms, each specializing in particular areas of the cell.[25] The cell increases the expression of antioxidant enzymes when subjected to rising ionizing radiation levels. However, if the amount of ROS overcomes these cellular defenses, the cell will experience damage (dose-dependent) that can lead to carcinogenesis, teratogenesis, necrosis or apoptosis. Anti-inflammatory and antioxidant compounds can control free radical generation, eliminate free radicals and induce natural development of antioxidants (such as SOD, GSH, and CAT). They improve DNA repair, suppress many inflammatory reactions, or stay cell division, allowing cells to undergo apoptosis process longer.[26]

The GSH detoxification system is important in cellular defense against a large group of injurious agents. GSH can protect against free radicals and cell death after various inflammation reactions.[27] Like the GSH and antioxidant enzymes, the endogenous protection mechanism defends against oxidative damage under normal conditions. GSH is a flexible protector and performs its protective function by free radical scavenging, restoring the damaged molecules by contributing hydrogen, reducing peroxides and retaining protein thiols in a reduced state.[28]

Thus in the croton induce hemorrhoid group, a substantial decrease in GSH content was observed compared to the normal group. That may be due to its increased usage as an attempt to detoxify the injury-generated free radicals. FRETP and FREMA treatment did not substantially affect the endogenous GSH content, but it protected against croton-induced GSH depletion. Results of the study was suggested that endogenous non-protein sulfhydryl GSH content is restored by the



flavonoid-rich extracts of both plants. The antioxidative and free- radical scavenging effects of *Tephrosia purpurea* and *Martynia annua* and presence of ingredients extensively reported.[29]

Flavonoids such as quercetin act as health-promoting substances as they have antioxidant and anti-inflammatory properties.[30] In the inflammation phase, macrophages and neutrophils are attracted to the injured tissues that release inflammatory mediators, such as tumor necrosis factor alpha (TNF- $\alpha$ ) and interleukin-1 (IL-1). Neutrophils contain high levels of destructive proteases and oxygen free radicals released into the wound area when cells die. This can cause extensive tissue damage and prolong the inflammatory phase. These free radicals are produced during oxidative stress, which causes lipid peroxidation, DNA breakage and scavenging enzymes inactivation. In case of hemorrhoid, one of the major causes of delayed healing is the persistence of inflammation or inadequate angiogenic response.[31] It has been postulated that an anti-inflammatory response after cutaneous wound induction is a prerequisite for healing.[32] Potent antioxidant, anti-inflammatory agents such as quercetin can play an important role in restoring physiological conditions, allowing a significant improvement in hemorrhoid healing.

## REFERENCES

- [1] Lohsiriwat V. Hemorrhoids: from basic pathophysiology to clinical management. World Journal of Gastroenterology. 2012;18(17):2009- 2017. Available from doi: 10.3748/wjg.v18.i17.2009
- [2] Margetis N. Pathophysiology of internal hemorrhoids. Annals of Gastroenterology. 2019;32(3):264 -272 . Available from doi:10.20524/aog.2019.0355
- [3] Kumar A, Dutta M, Bhatt TK, Dalal DS. Use of herbal tonic Yakrifit in equine practice. Indian Veterinary Journal. 1997;74(5):424-425. Available from <http://indianmedicine.eldoc.ub.rug.nl>
- [4] Sankaran JR. Tefroli in the Management of Viral Hepatitis. The Antiseptic. 1980;77(11),643-646.
- [5] Kirtikar KR, Basu BD. Indian Medicinal Plants. Vol. 1, (2nd edition)
- [6] Lalit Mohan Basu, Allahabad, India, 1956: 723.
- [7] Deshpande SS, Shah GB, Parmar NS. Antiulcer activity of *Tephrosia purpurea* in rats. Indian Journal of Pharmacology. 2003;35:168-172. Available from <https://www.ijp-online.com>
- [8] Agarkar SP. Medicinal plants of Bombay Presidency. Scientific Publishers Jodhpur, India. 1991; 209-210.
- [9] Chopra RN, Nayer SL, Chopra IC. Glossary of Indian Medicinal Plants. New Delhi, India: Council of Scientific and Industrial Research. 1956; 256-258.
- [10] Chatpalliwar VA, Joharapurkar AA, Wanjari MM, Chakraborty RR, Kharkar VT. Anti-inflammatory activity of *Martynia diandra* GLOX. Indian Drugs. 2002;39(10),543-545.
- [11] Amdekar S, Roy P, Singh V, Kumar A, Singh R, Sharma P. Anti- Inflammatory Activity of Lactobacillus on Carrageenan-Induced Paw Edema in Male Wistar Rats. International Journal of Inflammation. 2012;2012:752015. Available from doi: 10.1155/2012/752015.
- [12] Amann R, Schuligoi R, Lanz I, Donnerer J. Histamine induced edema in the rat paw-effect of *Capsaicin denervation* and a CGRP receptor antagonist, European Journal of Pharmacology. 1995;279:227-31. Available from doi: 10.1016/0014-2999(95)00169-L.
- [13] Dray A. Inflammatory mediators of pain. British Journal of Anesthesia, 1995;75:25-131. Available from doi: 10.1093/ bja/75.2.125
- [14] Azeemuddin M, Viswanatha GL, Rafiq M, Thippeswamy AH, Baig MR, Kavya KJ, Patki PS, Shyam R. An improved experimental model of hemorrhoids in rats: evaluation of antihemorrhoidal activity of an herbal formulation. ISRN Pharmacology. 2014;1-7. Available from doi: 10.1155/2014/530931.
- [15] Moron MA, Depierre JW, Mannervick B. Levels of glutathione, glutathione reductase and glutathione S-transferase activities in rat lung and liver. Biochimica et Biophysica Acta. 1979;582(1):67-78. Available from doi: 10.1016/0304-4165(79)90289-7.
- [16] Ohkawa H, Ohishi N, Yagi K. Assay for lipid peroxides in animal tissues by thiobarbituric acid reaction. Analytical Biochemistry. 1979;95:351-358. Available from doi: 10.1016/0003- 2697(79)90738-3.
- [17] Beers RF, Sizer IW. A spectrophotometric method for measuring the breakdown of hydrogen peroxide by catalase. Journal of Biological Chemistry. 1952;195:133-140.
- [18] Misra HP, Fridovich I. The role of superoxide anion in the autooxidation of epinephrine and a simple assay for superoxide dismutase. Journal of Biological Chemistry. 1972;247:3170-3175. Available from <https://pubmed.ncbi.nlm.nih.gov/4623845>
- [19] Mcmanus JF, Mowry RW. Staining Methods: Histologic and Histochemical Harper and Row/New York,



Evanston/London. 1965:135-143.

- [20] Badgujar VB, Jain PS, Patil RR, Haswani NG, Chaudhari SG. Anti-inflammatory activity of *Helicteres isora* L. stem bark extracts in rats. Asian Journal of Pharmaceutical and Clinical Research. 2009;2:63–65. Available from <https://innovareacademics.in/journal/ajpcr>
- [21] Kumar SS, Sivakumar T, Chandrasekar MJ, Suresh B. Evaluation of anti-inflammatory activity of *Eclipta alba* in rats. Ancient Science of Life. 2005;24(3):112–118. Available from <http://www.ancientscienceoflife.org>
- [22] Odukaoya OA, Sofiyada MO, Ilori OO, Gbededo MO, Ajadotuigwe JO, Olleye OO. Hemorrhoid therapy with medicinal plants: Astringency and inhibition of lipid peroxidation as key factors. International Journal of Biological Chemistry. 2009;3(3):111-118. Available from doi: 10.3923/ijbc.2009.111.118.
- [23] Atta AH, Alkofahi A. Anti-nociceptive and anti-inflammatory effects of some Jordanian medicinal plant extracts. Journal of Ethnopharmacology. 1998;60:117-24. Available from doi: 10.1016/s0378-8741(97)00137-2.
- [24] Wang F, Liu S, Shen Y, *et al.* Protective effects of N-acetylcysteine on cisplatin-induced oxidative stress and DNA damage in HepG2 cells. Experimental and Therapeutic Medicine. 2014;8(6):1939-1945. Available from doi: 10.3892/etm.2014.2019
- [25] Carol AF, Timothy MW. Cytokines in acute and chronic inflammation. Frontiers in Biology. 1997;12–26. Available from doi: 10.2741/A171
- [26] Holley AK, Miao L, St Clair DK, St Clair WH. Redox-modulated phenomena and radiation therapy: the central role of superoxide dismutases. Antioxid. Redox. Signal. 2014;20(10):1567–89. Available from doi: 10.1089/ars.2012.5000.
- [27] Pei H, Chen W, Hu W, Zhu M, Liu T. GANRA-5 protects both cultured cells and mice from various radiation types by functioning as a free radical scavenger. Free Radical Research. 2014; 48(6):670–8. Available from doi: 10.3109/10715762.2014.898843.
- [28] Biaglow JE, Varnes AM, Epp ER, Clark EP. In: Cerrutti PA, Nygaard OF, Simic MG, eds. The role of thiols in response to radiation and drugs. Anticarcinogenesis and Radiation Protection. New York, NY: Plenum Press; 1987:387.
- [29] Bump EA, Brown JM. Role of glutathione in the radiation response of mammalian cells in vitro and in vivo. Pharmacology & Therapeutics. 1990;47:117-136. Available from doi: 10.1016/0163-7258(90)90048-7.
- [30] Elzaawely A, Xuan T, Koyama H, Tawata S. Antioxidant activity and contents of essential oil and phenolic compounds in flowers and seeds of *Alpinia zerumbet* (Pers.) B.L. Burtt. & R.M. Sm. Food Chemistry. 2007;104(4):1648–53. Available from 10.1016/j.foodchem.2007.03.016
- [31] Kleemann R, Verschuren L, Morrison M, Zadelaar S, Van Erk MJ, Wielinga PY, Kooistra T. Anti-inflammatory, anti-proliferative and anti-atherosclerotic effects of quercetin in human in-vitro and in-vivo models. Atherosclerosis. 2011;218: 44-52. Available from doi: 10.1016/j.atherosclerosis.2011.04.023.
- [32] Martin A. The use of antioxidants in healing. Dermatologic Surgery. 1996;22(2):156-160. doi: 10.1111/j.1524-4725.1996.tb00499.x.
- [33] Castangia I, Nácher A, Caddeo C, Valenti D, Fadda AM, Díez-Sales O, Ruiz-Saurí A, Manconi M. Fabrication of quercetin and curcumin bionanovesicles for the prevention and rapid regeneration of full-thickness skin defects on mice. Acta Biomaterialia. 2014; 10:1292-1300. Available from doi: 10.1016/j.actbio.2013.11.005.