

ORIGINAL ARTICLE

Comparison of Early Surgical Outcomes following Anoplasty and Limited PSARP for Perineal Fistula

Bruno Martinez-Leo,* Vicente Herrera-Del Prado, Victor Portugal-Moreno, Arturo Godoy-Esquivel, Adriana Castillo-Aguirre, Luis Velasco-Soria, Luis Garcia-Cabello, Miguel Vargas-Gomez

Pediatric Surgery Division, Moctezuma Children's Hospital, Mexico City Health Secretariat, Mexico

This is an open-access article distributed under the terms of the Creative Commons Attribution License, which permits unrestricted use, distribution, and reproduction in any medium, provided the original work is properly cited.

ABSTRACT

Background: To present the early surgical outcomes of two different surgical methods for the treatment of perineal fistula in patients with anorectal malformation.

Material and Methods: Retrospective chart analysis of patients treated with any of the two surgical approaches for perineal fistula treatment during the newborn period, without a colostomy at Academic and Community Pediatric Surgery Reference Hospital during October 1st, 2015 to December 31st, 2018.

Results: Twenty-six out of 57 patients of our database met inclusion criteria during the study period. 15 in the anoplasty group and 11 in the Minimal Posterior Sagittal Anorectoplasty (MPSARP); the anoplasty group had more rate of anoplasty dehiscence (4 partial, 6 total – requiring additional stitches, $p = 0.027$), versus zero in the MPSARP group, albeit there was 1 superficial perineal dehiscence. All surgeries were performed without a previous colostomy. There were no other surgical complications reported, and there was no difference in age, weight, sacral ratio, and associated malformations.

Conclusion: Minimal PSARP can be safely done in the newborn patient with a patent perineal fistula.

Key words: Imperforate anus; Anorectal malformation; Perineal fistula; Colostomy

INTRODUCTION

Recto-perineal fistula is the most frequent type of anorectal malformation, ranging from 30% - 57% among different series, [1-4] and males are slightly more affected than females. When not associated with sacral defects or other urological malformations, and given the proper operation, functional prognosis is excellent.[5] Two surgical managements are predominantly used for its management: a simple anoplasty using a Heineke-Mikulicz type of incision, or “cutback” operation, first reported by Dennis Browne[6], in which rectal mucosa is exposed and sutured to the skin or, similar enough, the Hendren approach which involves the construction of flaps to further open the fistula and allow normal defecation, [7] all of them without rectal mobilization; and -on the other hand- a minimal posterior sagittal anorectoplasty (MPSARP) which involves limited mobilization of the rectum to place it into the inferior limits of sphincter complex and open a neo-anus within the limits of the parasagittal fibers. Since patients with recto-perineal fistula represent 52% of all the ano-

rectal malformations included in our colorectal database, we decided to retrospectively compare early surgical outcomes of both approaches in the patients treated at our institution in order to determine the best surgical approach.

MATERIALS AND METHODS

We reviewed the clinical charts of patients with diagnosis of perineal fistula treated at our hospital from October 1st, 2015 to December 31st, 2018. Patient's demographic and somatic data, early and intermediate surgical outcomes were recorded from both medical charts and a prospective colorectal database which was started on September 2015 that systematically registers all patients with congenital colorectal diseases treated at this institution. Decision on performing an anoplasty or a MPSARP depended on the attending pediatric surgeon in charge of each case. Techniques used for anoplasty and MPSARP were performed as described elsewhere [5, 6].

Descriptive statistics and the Fisher exact test were used to analyze the data ($p < 0.05$ defined as sig-

Correspondence*: Bruno Martinez-Leo, Pediatric Surgery Division, Moctezuma Children's Hospital, Mexico City Health Secretariat, Mexico

E mail: bruno.martinezleo@gmail.com

Submitted: 18-02-2020

Conflict of interest: None

© 2020, Martinez-Leo et al

Accepted: 22-04-2020

Source of Support: Nil

nificant) using Microsoft Office Excel Software v. 1904 (Richmond, VA, USA). Partial anoplasty dehiscence was defined as < 25% of total neoanus circumference without the need of additional stitches, while “total” was defined as > 25% dehiscence requiring stitches (Fig. 1). Superficial perineal dehiscence was defined as separation of only skin borders without need for additional stitches, while deep perineal dehiscence as a dehiscence deeper than hypodermis layer requiring additional stitches.

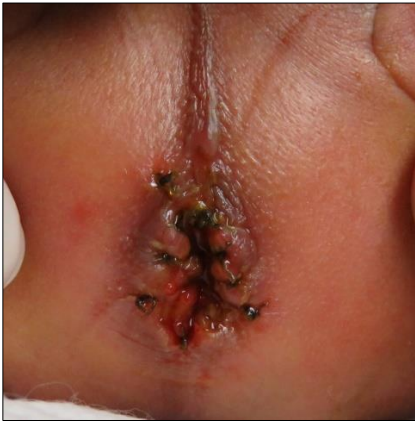

Figure 1. Early dehiscence of a simple anoplasty, >25% of total circumference, requiring additional stitches.

RESULTS

Out of 57 patients with recto-perineal fistula treated in the study time period, 26 patients were operated during their newborn age. Patients older than 28 days, having major sacral, cardiac or genital malformations and /or a colostomy done were excluded from the analysis. Fifteen patients received a primary anoplasty (AG group) and 11 a MPSARP approach (MG). All of them were operated in prone position with elevation of the pelvis, with a Föley catheter placed in the urethra, and fine 5-0, long-term absorbable sutures were used. Mean age, weight, length of stay, sacrum index, operating room time, intraoperative bleeding, days to start enteral feedings and Hegar dilator calibration are summarized in Table 1. All patients had normal kidneys, normal sacrum and absence of major malformations. None of these variables yielded in significant statistical differences. Partial anoplasty dehiscence was reported in 4 patients in the AG versus 0 in the MG, superficial perineal dehiscence was zero in the AG vs 1 in the MG ($p = 0.1134$). No deep perineal dehiscence were reported. Total anoplasty dehiscence was reported in 6 patients in the AG, while no patients suffered from this complication in the MG ($p=0.0237$), and all of them required an additional procedure done in the operating room (OR) to place additional stitches. No deaths, surgical site infections, or real (fibrotic) anal stenosis 14 days after surgery were reported among both groups.

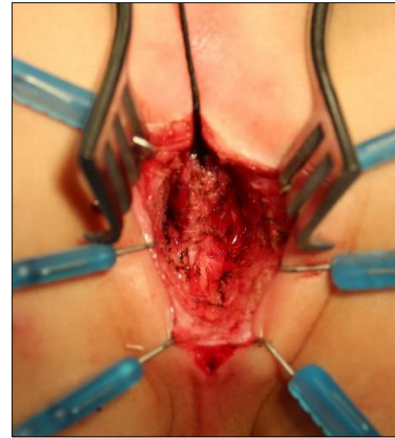


Figure 2. Rectum being dissected off spongiosum body during a MPSARP.

DISCUSSION

Forty percent of the patients in the anoplasty group required an additional visit to the OR to have additional stitches due to dehiscence, which increased anesthesia exposure, fasting time, surgical trauma and potential respiratory, transportation and anesthetic complications. OR time required and blood loss was higher in the MG. One patient suffered from a 90 mL blood loss due to persistent hemorrhage during the spongiosum body dissection, requiring red-cell pack transfusion during the operation and a longer stay in the OR, since extubation period was larger than expected. Even though this event was not statistically significant ($p = 0.45$), it shows a theoretical increased risk for the individual patient since the circulating blood volume for a term newborn has been estimated to an average of 85 mL/kg.[8] This increased risk can be partially explained by the fact that 45% of the MG patients were male: during a MPSARP in male cases, a meticulous separation of the rectum from the spongiosum body is required (Fig. 2), raising the possibility of bleeding and prolonged OR time; although it is a rather small procedure it is a technically demanding one, [5] and the surgical team must be prepared for such outcome, even if it only happened once in our series. MPSARP allows the rectum to be placed within the final aspects of levator muscle, to perform an adequately sized neoanus within the limits of the sphincter, with a proper size-for age (12 mm in a full term newborn),[9] thus allowing rectal dilations to be easier, as well as adequate functional and cosmetic results.[5, 9] Given that this type of malformation belongs to the good (i.e. benign) side of the ARM spectrum, can be carried out without the use of a colostomy [10, 11] and if the patient's clinical conditions allow it to be safe.[12] Another important prognostic aspect to consider is the fact that presacral masses seem to be more frequently present in patients with perineal fistulas:[13, 14] none of the patients in this series had sacrum malformations, which offered a

more homogeneous sample in terms of prognosis. We believe that the decreased dehiscence rate in our patients with MPSARP is partially explained by the mobilization of the distal end of the rectum and suturing it to the skin border with no tension (Fig. 3). The MPSARP also allowed performing an adequate size-for-age neoanus, which allows a shorter time to taper and stop dilatations. We consider that MPSARP should be offered to these patients as a primary repair. In our patients, we think that the repair of this type of defect should not be done on an urgent basis, proven the patient is passing meconium through the fistula and the abdomen is not distended. If the patient's conditions are not well enough to tolerate a surgical procedure, fistula dilatations can be performed using Hegar dilators while the clinical conditions improve, as a temporizing preliminary procedure,[5] allowing the patient to overcome the time required for pulmonary adaptation and a careful evaluation and screening for associated malformations. It cannot be over emphasized that the surgical management of this malformation requires a meticulous technique [15], surgeon's familiarity with the rectal anatomy and surrounding structures in the patient with ARM and having proper fine suture/needle materials available. It has been reported that there is no difference in constipation rate, and bowel movements per day when comparing anoplasty versus MPSARP in older male patients treated at older ages than newborn period, but the authors also report a higher complication rate in their PSARP group, as well as a higher colostomy rate [10]. To our knowledge this is the first paper that compares both

techniques performed during the newborn period to surgically treat perineal fistula.

We acknowledge the main limitations of our study, such as small sample size, a subjective cutoff percentage of 25% of anoplasty loss to define minor versus major dehiscence in addition to several surgeons performing the procedures. A further analysis with a larger sample is required to support the findings of this study, as well as medium- and long-term functional outcomes.

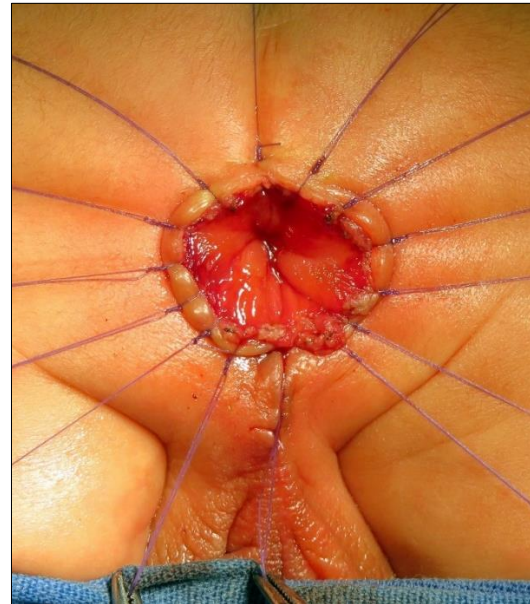


Figure 3. Final step of MPSARP: anoplasty performed with no tension, before cutting off sutures.

Table 1: Comparison of both groups:

	Anoplasty	MPSARP	Notes
	15 (60%)	11 (40%)	
Male	11	5	
Female	4	6	
Mean Age at Surgery (d)	2.4	4.3	
Sacrum Index AP	0.79 (n = 12)	0.71 (n = 6)	
Sacrum Index Lateral	0.85 (n = 11)	0.82 (n = 6)	
OR Time (min)	54.6 (20-150)	139 (65-270)	
Bleeding (mL)	3.7 (1-10)	29 (5-90)	
Superficial Perineal Dehiscence	0	1	p = 0.1134 (ns)
Reoperations	6	0	p = 0.027 (s)
Hegar calibration at the end of surgical procedure	8.8 (5-12)	11 (8-12)	
Days to oral feeding after final surgery	3.9	3.7	
LOS (d)	12	7.8	

(d = days, AP = Anteroposterior, OR = operating room, min = minutes, mL = milliliters, LOS = Length of stay, ns = not significant)

CONCLUSION

Minimal PSARP with no colostomy has fewer complications in our series than simple anoplasty and can be offered as an initial surgical option for patients suffering from perineal fistula. Perineal fistula can be safely treated using a Minimal Posterior Sagittal Anorectoplasty. Meticulous technique must be used specially when dissecting rectum off urethra in males and vagina in females. A tension-free anoplasty seems to decrease the risk of dehiscence.

REFERENCES

1. Chen CJ. The treatment of imperforate anus: experience with 108 patients. *J Pediatr Surg.* 1999; 34:1728-32.
2. Julia V, Tarrado X, Prat J, Saura L, Montaner A, Castanon M, et al. Fifteen years of experience in the treatment of anorectal malformations. *Ped Surgery Int.* 2010; 26:145-9.
3. Martinez-Quiroz R, Montoya-Reales D, Rodas-Andino J. Malformaciones Anorrectales: Diagnóstico y tratamiento. Cinco años de experiencia, Honduras. *Revista medica hondurena.* 2016; 84:36-40.
4. Endo M, Hayashi A, Ishihara M, Maie M, Nagasaki A, Nishi T, et al. Analysis of 1,992 patients with anorectal malformations over the past two decades in Japan. Steering Committee of Japanese Study Group of Anorectal Anomalies. *J Pediatr Surg.* 1999; 34:435-41.
5. Peña A, Bischoff A. Surgical treatment of colorectal problems in children. 1 ed. Peña A, Bischoff A, editors: Springer International Publishing; 2015.
6. Browne D. Some Congenital Deformities of the Rectum, Anus, Vagina and Urethra: Hunterian Lecture delivered at the Royal College of Surgeons of England on 9th February, 1950. *Ann Royal Coll Surg Eng.* 1951; 8:173-92.
7. Hendren WH. Constipation caused by anterior location of the anus and its surgical correction. *J Pediatr Surg.* 1978; 13:505-12.
8. Matthews DC, Glader B. Erythrocyte disorders in infancy. In: Gleason CA, Devaskar DU, editors. *Avery's Diseases of the Newborn.* 9th ed. Philadelphia, PA: Elsevier Saunders; 2012. p. 1498.
9. Peña A. Atlas of surgical management of anorectal malformations: Springer-Verlag, New York Inc.; 1990. 104 p.
10. Pakarinen M, Goyal A, Koivusalo A, Baillie C, Turnock R, Rintala R. Functional outcome in correction of perineal fistula in boys with anoplasty versus posterior sagittal anorectoplasty. *Pediatric Surgery Int.* 2006; 22:961-5.
11. Amanollahi O, Ketabchian S. One-stage vs. three-stage repair in anorectal malformation with rectovestibular fistula. *Afr J Paediatr Surg.* 2016; 13:20-5.
12. Kumar B, Kandpal DK, Sharma SB, Agrawal LD, Jhamariya VN. Single-stage repair of vestibular and perineal fistulae without colostomy. *J Pediatr Surg.* 2008; 43:1848-52.
13. Walton M, Bass J, Soucy P. Tethered cord with anorectal malformation, sacral anomalies and presacral masses: an under-recognized association. *Eur J Pediatr Surg.* 1995; 5:59-62.
14. Otagiri N, Matsumoto Y, Yoshida Y. Posterior sagittal approach for Currarino syndrome with anterior sacral meningocele: a case report. *J Pediatr Surg.* 2000; 35:1112-4.
15. Bischoff A, Levitt M, Peña A. Update on the management of anorectal malformations. *Pediatr Surg Int.* 2013; 29:899-904.

Consent: Author(s) declared taking informed written consent for the publication of clinical photographs/material (if any used), from the legal guardian of the patient with an understanding that every effort will be made to conceal the identity of the patient, however it cannot be guaranteed.

Author Contributions: Author(s) declared to fulfil authorship criteria as devised by ICMJE and approved the final version.