

## CASE REPORT

## Calcification and Airway Stenosis in a Neonate with Chondrodysplasia Punctata

Saurabh Garge\*

Consultant, Pediatric Surgery Unit, Amaltas Institute of Medical Sciences, Dewas

**How to cite:** Garge S. Calcification and airway stenosis in a neonate with chondrodysplasia punctata. *J Neonatal Surg.* 2019;8:6.

This is an open-access article distributed under the terms of the Creative Commons Attribution License, which permits unrestricted use, distribution, and reproduction in any medium, provided the original work is properly cited.

## ABSTRACT

Chondrodysplasia punctata (CDP) is a group of congenital bone and cartilage disorders. Laryngeal and tracheal calcification and subsequent stenosis are not frequently seen. We report here a case of an infant with CDP associated with tracheal stenosis.

**Key words:** Chondrodysplasia punctata; Airway stenosis; Tracheostomy

## INTRODUCTION

Calcification of the airways is rare in children [1]. It can be idiopathic or from known causes [1,2]. Genetic conditions such as X-linked recessive chondrodysplasia punctata (CDP) must be considered when there are clinical stigmata. CDP is a generic term for a group of skeletal dysplasia of varying genotypic and environmental etiology characterized by stippled epiphyses during infancy [1-5]. Laryngeal, tracheal calcification, and stenosis are associated infrequent finding [3]. CDP is essentially a radiological diagnosis; the cartilage stippling commonly involves epiphyseal end plates [1,2]. Involvement of tracheal cartilage may interfere with in utero tracheal development and cause critical airway narrowing in the postnatal period. Decannulation rates are low and death rates are high in severe airway stenosis [3]. We here describe a neonate with severe airway stenosis and typical radiological and facial stigmata of CDP.

## CASE REPORT

A male baby born at 36 weeks and weighing 2.1 kg presented with inspiratory stridor and severe respiratory distress since birth. Intubation proved difficult and was possible with a 2.0 Fr endotracheal tube. After intubation, the patient could be ventilated and had stable blood gases. On examination, the baby had midface hypoplasia, hypoplastic fingernails, and short limbs (Figure 1a). Chest X-ray demonstrated calcification in the tracheobronchial tree (Figure 1b). The lung fields were normal. Humeral epiphyses also showed

stippled calcifications; however, the long bones were normal (Figure 1b). Cardiac echocardiography was normal. Ophthalmological examination did not reveal any congenital cataracts. Rigid bronchoscopy revealed a subglottic narrowing; however, the neonatal bronchoscope could pass snugly across the narrowing. There was no associated tracheal stenosis. A 2.5 Fr endotracheal tube was passed after balloon dilation and the patient was shifted on ventilator. In anticipation of accidental extubation and difficult intubation, stay sutures were taken on trachea to facilitate emergency tracheostomy. The patient had a long course in the hospital with several failed decannulation attempts. He ultimately succumbed to ventilator-associated pneumonia and sepsis. Genetic studies for confirmation of diagnosis have not been attempted as the caretakers denied the same, due to cost issues.

## DISCUSSION

The presence of radiographic findings of stippled calcification around long bones, vertebral stippling, and airway involvement, characteristic phenotypic findings of midfacial hypoplasia with depressed nasal bridge, and absence of maternal history of warfarin/phenytoin/alcohol abuse or lupus suggested the diagnosis of CDP in our case [1-3].

There are three forms of CDP described [1,2]:

1. X-linked dominant form (Conradi-Hunermann syndrome) is due to a defect in cholesterol biosynthesis, resulting in asymmetric limb shortening, cataracts, and dermatologic abnormalities.

**Correspondence\*:** Dr. Saurabh Garge, Amaltas Institute of Medical Sciences, Dewas. Phone: 09630956311.

E-mail: saurabhgarge8@gmail.com

Submitted: 17-11-2018

Conflict of interest: None Declared

© 2018, Garge

Accepted: 19-12-2018

Source of Support: Nil

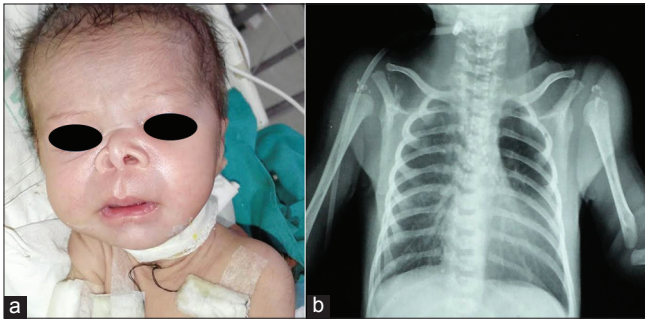


Figure 1: (a and b) Facial abnormalities and chest radiograph

2. Autosomal recessive rhizomelic form is caused by a defect in peroxisome enzymes, resulting in abnormal facies, rhizomelia, malformations of the long bones, cataracts, skin lesions, and mental retardation.
3. X-linked recessive form arises from a defect in the Vitamin K-dependent enzyme arylsulfatase E resulting in nasal and midface hypoplasia, mixed hearing loss, short stature, distal phalangeal hypoplasia, and cataracts.

There are very few reported cases of CDP with extensive airway involvement, most of which had a fatal outcome [3]. Tracheostomy has been advocated as a procedure in cases of severe tracheal stenosis [4,5]. Balloon dilatation can lead to success in few cases; however, definitive surgical intervention is yet to be defined [4]. Costal cartilage tracheoplasty and slide tra-

cheoplasty have been described, however, are less successful in severe cases [5].

## CONCLUSION

Characteristic radiological findings along with appropriate history, physical examination, and molecular and genetic testing can diagnose CDP accurately. In cases with severe airway complications, correct and early diagnosis of this rare entity can help in managing complications and improve survival.

## REFERENCES

1. Deepthi B, Chhapola V, Kanwal SK, Sharma AG, Kumar V. Chondrodysplasia punctata with severe airway stenosis. *Indian J Crit Care Med.* 2018;22:552-4.
2. Goussard P, Andronikou S, Semakula-Katende NS, Gie R. Calcification and airway stenosis in a child with chondrodysplasia calcificans punctata. *BMJ Case Rep.* 2014;2014:Bcr2014205087.
3. Dewan P, Rai A, Gupta N, Shah D, Faridi MM. A rare lethal case of chondrodysplasia punctata with extensive airway involvement. *Fetal Pediatr Pathol.* 2012;31:134-9.
4. Schweiger C, Nassar MN, Goebel D, Rutter MJ. Chondrodysplasia punctata presenting with tracheal obstruction. *Int J Pediatr Otorhinolaryngol.* 2017;93:100-2.
5. Wolpoe ME, Braverman N, Lin SY. Severe tracheobronchial stenosis in the X-linked recessive form of chondrodysplasia punctata. *Arch Otolaryngol Head Neck Surg.* 2004;130:1423-6.