

LETTER TO THE EDITOR

Sigmoid Colon Atresia in a Female with Imperforate Anus without Vestibular Fistula

Laraib Amjad Dudrah,* Nishant Singh, Nabila Talat

Department of Pediatric Surgery Unit 2, The Children's Hospital and the Institute of Child Health, Lahore

This is an open-access article distributed under the terms of the Creative Commons Attribution License, which permits unrestricted use, distribution, and reproduction in any medium, provided the original work is properly cited.

DEAR SIR

Colonic atresia is a rare congenital neonatal intestinal obstruction; rarer still is its association with anorectal malformations (ARM). Only a few cases have been reported in literature.[1,2] Herein, we report a case of rare ARM associated with sigmoid colonic atresia.

A 40-hour-old full-term female baby, weighing 2.5kg, born via normal vaginal delivery at some clinic, presented with abdominal distension, bilious vomiting and failure to pass meconium since birth. There was no history of consanguinity. The mother had poor antenatal follow-up. She was on calcium and vitamin D supplements during gestation. The baby tolerated few feeds initially but developed abdominal distention and non-bilious vomiting which later turned to bilious. On examination, the patient was dehydrated with grossly distended abdomen. Perineal examination revealed an imperforate anus with an obvious anal dimple, poorly developed gluteal muscles and presence of two perineal openings: urethra and vagina. No other physical abnormalities were noted. Invertogram revealed absent gas shadows in pelvis with distended gut loops (Fig.1). The patient was resuscitated with IV fluids and antibiotics and optimized for surgery. Initially a small inverted V-shaped incision was given in left iliac fossa for a sigmoid colostomy, but a sigmoid colonic atresia was noted. Therefore, exploratory laparotomy was done which revealed sigmoidal colon ending blindly at its mid part (type II colonic atresia) with proximal dilated segment and distal atretic sigmoid colon ending behind urinary bladder (Fig.2). Distal colon was probed, and saline injected via feeding tube. It was 3 to 4cm long with no external communication or any opening in perineum. Both ends of the atresia were exteriorized as colostomy. Post-operative recovery was uneventful, and the patient was discharged on 3rd post-operative day. First

follow up was done 10 days after surgery and the baby was doing fine.

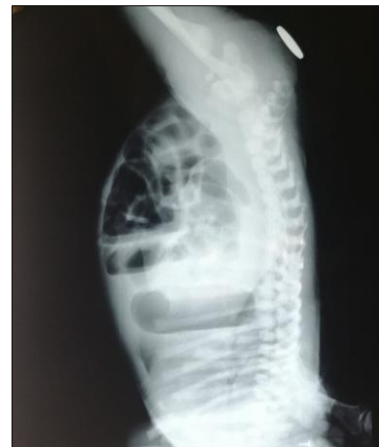

Figure 1: Invertogram showing high variety ARM.

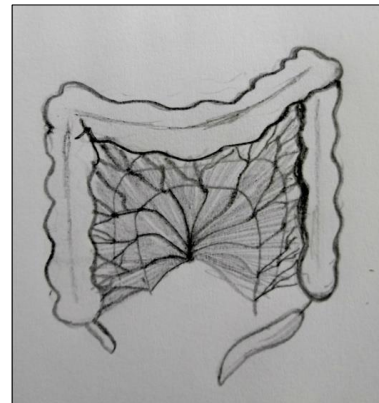


Figure 2: Sketch of sigmoid colonic atresia.

Vestibular fistula is the most common type of ARM in females. Imperforate anus without any perineal fistula is rarely encountered in female patients with ARM. Anorectal malformations are usually associated with various congenital anomalies such as VACTERL anomalies (Vertebral, Anorectal, Cardiac, Tracheo-Esophageal, Renal and Limbs).[1] Colonic atresia (CA) is also an exceedingly rare site of intes-

Correspondence*: Laraib Amjad Dudrah, Department of Pediatric Surgery Unit 2, The Children's Hospital and the Institute of Child Health, Lahore

E mail: l.a.dudrah@gmail.com
Submitted: 23-01-2020
Conflict of interest: None

©2019, Dudrah, et al
Accepted: 04-04-2020
Source of Support: Nil

tinal atresia.[4-6] ARM with CA is a very rare association, with only a few cases reported in literature.[2,3] In the index case, colonic atresia was associated with a very rare anorectal malformation in a female patient.

Both ARM and CA present with features of neonatal intestinal obstruction as encountered in our patient. Therefore, preoperative diagnosis of coexisting ARM and CA is challenging. Preoperative diagnosis may help in better surgical planning as to incision site. In the index case, we planned a sigmoid colostomy thus a small inverted V incision was given in left iliac fossa, and on encountering atresia, a laparotomy incision was given for better delineation of surgical findings, though, the same purpose can be served by extending the first incision. Different surgical approaches have been used to manage CA ranging from primary anastomosis to initial diversion.[4,6] Due to presence of ARM, primary repair of CA was not feasible; therefore, both ends of the stoma were exteriorized as temporary diversion. We have planned distal loop washouts before and anorectoplasty to mitigate the luminal disparity that may pose operative difficulty during stomal reversal.

Consent: Authors declared that they have taken informed written consent, for publication of this report along with clinical photographs/material, from the legal guardian of the patient with an understanding that every effort will be made to conceal the identity of the patient however it cannot be guaranteed.

Authors' Contribution: All the authors contributed fully in concept, literature review, and drafting of the manuscript and approved the final version of this manuscript.

REFERENCES

1. Maitra S, Sarkar R. Anorectal malformation associated with small and large bowel atresias: A rare association. *J Neonatal Surg.* 2012; 1:59.
2. Derenoncourt MH, Baltazar G, Lubell T, Ruscica A, Sahyoun C, Velcek F. Colonic atresia and anorectal malformation in a Haitian patient: a case study of rare diseases. *Springer Plus.* 2014; 3:203.
3. Petropoulos AS, Mouravas V, Kepertis C, Dimopoulos C, Roussis X. Imperforate anus associated with atresia of the transverse colon: a case report. *Eur J Pediatr Surg.* 2004; 14:290-2.
4. Hsu CT, Wang SS, Houng JF, Chaing PJ, Huang CB. Congenital colonic atresia: Report of one case. *Pediatr Neonatol.* 2010; 51:186-9.
5. Saha M. Alimentary tract atresias associated with anorectal malformations: 10 years' experience. *J Neonatal Surg.* 2016; 5:43.
6. Mirza B, Iqbal S, Ijaz L. Colonic atresia and stenosis: Our experience. *J Neonatal Surg.* 2012; 1:4.