

Case Report

© 2021 Fathima et al.

Submitted: 10-08-2021

Accepted: 23-10-2021

License: This work is licensed under a [Creative Commons Attribution 4.0 International License](https://creativecommons.org/licenses/by/4.0/).

DOI: <https://doi.org/10.47338/jns.v10.999>

Neonatal intussusception secondary to intestinal duplication cyst: A case report

Haseen Fathima,¹ Divya Mishra,¹ Nishanth Rajan,*¹ Joseph Manuel,² Manjiri Dilip Phansalkar,³ Ninan Zachariah,⁴

1 Department of Pediatrics, Pondicherry Institute of Medical Science, Puducherry

2 Department of Radio-diagnosis, Pondicherry Institute of Medical Science, Puducherry

3 Department of Pathology, Pondicherry Institute of Medical Science, Puducherry

4 Department of Pediatric Surgery, Pondicherry Institute of Medical Science, Puducherry

Correspondence*: Dr. Nishanth Rajan, Associate Professor, Department of Pediatrics, Pondicherry Institute of Medical Science, Puducherry- 605014, India. **E-mail:** nishanthwolverine@gmail.com

KEYWORDS

Duplication cyst,
Intestine,
Intussusception,
Neonate,
Bleeding per rectum

ABSTRACT

Background: Intussusception is a rare cause of bleeding per rectum in neonates. Duplication cyst as a pathological lead point for intussusception is rarer too.

Case Presentation: A female neonate presented with bilious vomiting and bleeding per rectum. Ultrasonography diagnosed it as intussusception. Intraoperatively, on reduction of intussusception, a mass was found which on histopathological examination (HPE) revealed a duplication cyst.

Conclusion: A high index of suspicion is required for an early diagnosis of neonatal intussusception, which is essential for preventing complications and mortality.

INTRODUCTION

The common causes of bleeding per rectum in neonates are Necrotizing enterocolitis, sepsis, cow's milk protein allergy, congenital gut anomalies like malrotation, volvulus, and hemorrhagic disease of newborns.[1] Intussusception is a rare clinical entity in newborns.[2] The incidence of intussusception is 1-4/1000 live births with a male to female ratio 3:2.[3] Herein we describe a case of a female neonate who presented with bilious vomiting and blood in stools which was initially thought to be malrotation.

CASE REPORT

A 3.48kg female baby was born at 39 weeks of gestation. The antenatal period was uneventful with normal antenatal scans. The baby passed meconium at birth and was on exclusive breastfeeds. At 36 hours of life, the baby had 2 episodes of bilious vomiting. There was no tachycardia or fever, no abdominal distension, or palpable mass. There was no dyselectrolytemia, C reactive protein was negative, and the baby was hemodynamically stable. Nasogastric tube aspirate was light bilious, and the baby started passing a small quantity of mucus with minimal blood staining. The Apt test was indicative of fetal hemoglobin. Plain X-Ray of the abdomen showed dilated bowel loops in the periphery. Based on the history and examination a diagnosis of malrotation or

early-onset sepsis was made, and intravenous antibiotics were started.

After one day of conservative management, the baby started passing red currant jelly stools. Ultrasound abdomen showed the characteristic target sign, suggestive of intussusception. The baby was taken up for exploratory laparotomy. Intraoperatively, an ileocecolic intussusception (Fig.1) was found, which was manually reduced. On palpation of caecum, an intraluminal mass was palpable. Resection of ileum, caecum with the appendix, and 4cm of ascending colon were done followed by ileocolic anastomosis.

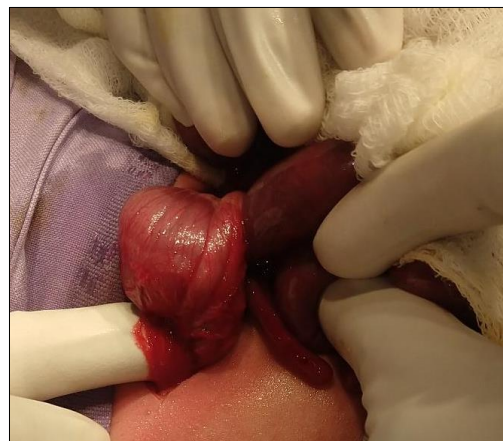


Figure 1: Intraoperative image showing ileocecolic intussusception.

The postoperative period was uneventful, and breastfeeding was started by the 5th POD. Histopathological examination revealed cystic duplication lined by primitive epithelium suggestive of duplication cyst (Fig.2).

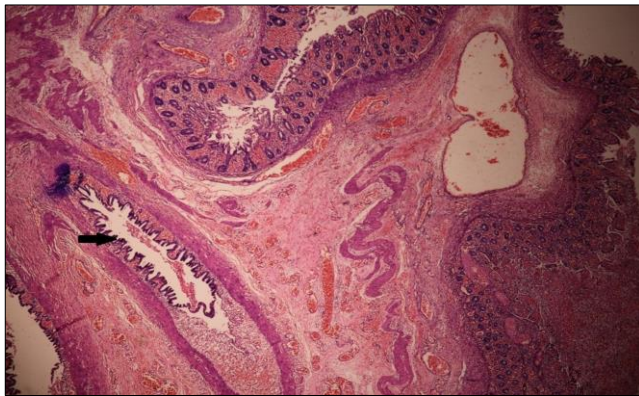


Figure 2: Histopathology picture of colonic mucosa with ischemic changes. Underlying cystic duplication lined by primitive epithelium (Black arrow)

DISCUSSION

Intussusception is an invagination of a segment of the intestine into another segment. Neonatal intussusception is only 0.3% of all intussusceptions.[2] But hardly a few case reports are available in the literature about neonatal intussusception secondary to intestinal duplication cyst.

Duplication cysts are a rare anomaly occurring during the development of the gut. They are epithelial-lined structures present in the mesenteric border of the intestine.[4] Around 70% of the cysts are diagnosed

during the first 2 years of life. Enteric duplication cysts are rare, about 1:4500 live births. Ileal cysts account for 53% of cases and intussusception can be a presenting modality.[4] Partial twinning in the foregut or hindgut, persistent endo-mesenchymal tract between amnion and yolk sac, the persistence of embryological diverticula, and aberrant recanalization of the lumen are a few among many theories proposed for the development of duplication cysts.[5] There are two varieties, tubular (communicating-20%) and cystic (non-communicating-80%).[6] Usually, cystic variety acts as a lead point for intussusception as it exerts pressure on the lumen, at times for volvulus also [5] and can have a clinical presentation of intestinal obstruction which can present as nausea, vomiting, irritability, abdominal distension, and mass.[4] Duplication cyst can have ectopic gastric mucosa which can cause ulceration, hemorrhage, and perforation.[5]

Dilated bowel loops on antenatal ultrasonography can suggest intestinal obstruction and occasionally pick up duplication cyst. Postnatal diagnosis of intussusception is mainly supported by ultrasonography, however, when the clinical symptoms and signs are non-specific, an upper GI contrast study has to be done to rule out malrotation and volvulus.[5] But in our case, antenatal ultrasounds were normal and there were dilated bowel loops on plain radiograph, which was described as the most common abnormality by Avasino et al.[7] A tabular presentation of reported neonatal intussusception and outcomes is illustrated in Table 1.

Table 1: Summary of few reported cases of neonatal intussusception.

Sr. No.	Author/ Year	No. of cases	Sex	Gestational status	Clinical features	Mode of diagnosis	Surgical procedure	Lead point	Outcome
1.	Veerabhadra 2019 [1]	1	Male	Term	Bleeding per rectum and shock on day 6 of life	Ultrasound- ileocolic intussusception	resection and end to end anastomosis	Nil	Uneventful
2.	Loukas 2009 [8]	1	Female	Preterm	Bilious vomiting on day 7 of illness	Upper GI study suggested incomplete obstruction. Peroperatively intussusception was seen	Reduction	Nil	Uneventful
3.	Tepmalai 2017 [9]	1	Male	Preterm	Abdominal wall erythema and abdominal distension	Peroperatively ileo-ileal intussusception was seen.	Reduction of the gut	Nil	Uneventful
4.	Sunil 2018 [2]	1	Male	Preterm	Feed intolerance, abdominal distention and recurrent apneas on day 8 of life.	Ileo-ileal intussusception was found peroperatively	Resection and anastomosis	Nil	Uneventful
5.	Hukeri 2019 [10]	1	Male	Preterm	bilious vomiting and progressive abdominal distension	exploratory laparotomy which revealed a jejunojejunal intussusception with gangrenous areas	Resection anastomosis	Nil	Died on day 3 post operatively

Other anomalies like spina bifida, cardiac or urinary malformations are reported in around 20% of children with duplication cysts. Digestive problems are also associated with 10% of children. Thus, any child diagnosed with a duplication cyst, a search for other anomalies is also to be made.[11]

To conclude, Intussusception should be ruled out in a neonate with bilious vomiting and blood in stools when there are no signs of sepsis and/or NEC. Ultrasound is the modality of choice.

REFERENCES

1. Radhakrishna V, Jindal B, Naredi BK, Balachander B, Nivedita M. Neonatal intussusception: A rare but important cause of bleeding per rectum in a neonate. *Trop Gastroenterol.* 2019; 39:37–9.
2. Pawar SJ, T S, Reddy S, Chethi S. A case report, ileo-ileal intussusception in preterm neonate: An unusual location. *Acad J Pediatr Neonatol.* 2018; 6:1–2.
3. Hassan A, Zain M, Ghazaly Y. Primary neonatal ileoileal intussusception. *J Pediatr Surg Case Rep.* 2019; 41:18–20.
4. Sharma S, Yadav AK, Mandal AK, Zaheer S, Yadav DK, Samie A. Enteric duplication cysts in children: A clinicopathological dilemma. *J Clin Diagn Res. JCDR.* 2015; 9:EC08-EC11.
5. Joshi SB, Muddashetty R, Patel HBN. Duplication cyst presenting as intussusception: Report of two cases. *Int J Anat Radiol Surg.* 2016; 5: SC01-SC03.
6. Domajnko B, Salloum RM. Duplication cyst of the sigmoid colon. *Gastroenterol Res Pract.* 2009; 918401. <https://doi.org/10.1155/2009/918401>.
7. Avansino JR, Bjerke S, Hendrickson M, Stelzner M, Sawin R. Clinical features and treatment outcome of intussusception in premature neonates. *J Pediatr Surg.* 2003; 38:1818–21.
8. Loukas I, Baltogiannis N, Plataras C, Skiathitou AV, Siahaniidou S, Geroulanos G. Intussusception in a premature neonate: A rare often misdiagnosed cause of intestinal obstruction. *Case Rep Med.* 2009;2009. <https://doi.org/10.1155/2009/607989>.
9. Tepmalai K, Naowapan T, Singhavejsakul J, Laohapensang M, Khorana J. Intussusception in premature baby: unusual cause of bowel obstruction and perforation. *J Neonatal Surg.* 2017; 6:13.
10. Hukeri AR, Gupta A, Kothari P, Dikshit V, Kekre G, Deshmukh S, et al. Bowel intussusception in premature baby: Needs high degree suspicion for early detection. *J Clin Neonatol.* 2019; 8:57.
11. Rasool N, Safdar CA, Ahmad A, Kanwal S. Enteric duplication in children: clinical presentation and outcome. *Singapore Med J.* 2013; 54:343-6. <https://doi.org/10.11622/smedj.2013129>.

Acknowledgements: Nil

Conflict of Interest: None

Source of Support: Nil

Consent to Publication: Author(s) declared taking informed written consent for the publication of clinical photographs/material (if any used), from the legal guardian of the patient with an understanding that every effort will be made to conceal the identity of the patient, however it cannot be guaranteed.

Author Contributions: Author(s) declared to fulfil authorship criteria as devised by ICMJE and approved the final version.