

Case Report

© 2020, Mittal et al

Submitted: 16-07-2020

Accepted: 16-08-2020

License: This work is licensed under a [Creative Commons Attribution 4.0 International License](https://creativecommons.org/licenses/by/4.0/).

DOI: <https://doi.org/10.47338/jns.v9.550>

A fatal combination of duodenal atresia with preduodenal portal vein, malrotation, and hypoplastic left heart syndrome: A case report

Priyanka Mittal, Nitin J Peters,* Ram Samujh

Department of Pediatric Surgery, Advanced Pediatric Centre, Post Graduate Institute of Medical Education and Research, Chandigarh, India

Correspondence*: Dr. Nitin J Peters, Assistant Professor, Department of Pediatric Surgery, Advanced Pediatric Centre, Post Graduate Institute of Medical Education and Research, Chandigarh, India.

E-mail: nitinjamespeters@yahoo.com

KEYWORDS

Duodenal atresia,
Preduodenal portal vein,
Hypoplastic left heart syndrome,
Malrotation

ABSTRACT

Background: Duodenal atresia (DA) is often associated with anomalies that include annular pancreas, cardiac anomalies, intestinal malrotation, situs inversus, or splenic anomalies. Association of duodenal atresia with complex cardiac anomalies is scarcely reported in the literature.

Case Presentation: A term neonate was diagnosed with duodenal atresia and found to have a preduodenal portal vein and malrotation. A gastro jejunostomy was added to the procedure, due to the pre duodenal portal vein. On post-operative day 4, the patient had sudden desaturation. The respiratory system was normal and there was no evidence of septicaemia. On the post-operative echocardiogram, the diagnosis of hypoplastic left heart was made and the patient eventually succumbed to his complex cardiac disease.

Conclusion: This is a rare combination of multiple anomalies and we report the clinical and anatomical findings of this patient.

INTRODUCTION

Duodenal atresia (DA) is the commonest cause of congenital duodenal obstruction. DA is often associated with anomalies that include annular pancreas, cardiac anomalies, intestinal malrotation, situs in versus or splenic anomalies.[1] Preduodenal portal vein(PDPV) is not an uncommon finding in such patients.[2] Association of duodenal atresia with multiple anomalies, especially complex cardiac anomalies, has been scarcely reported in literature.

Here we report the clinical and anatomic findings of a neonate with DA, associated with intestinal malrotation, PDPV, and hypoplastic left heart syndrome (HLHS). This is a rare and challenging combination of congenital anomalies. We report this fatal case, which is the first to be reported to the best of our knowledge, and review the available literature.

CASE REPORT

We report a referred case of a 12 days old male neonate, born vaginally to 28 years old, gravida 2 mother. The pregnancy was antenatally supervised at a primary health centre but no records of antenatal ultrasound were available. The mother had no history of

any drug intake, no history of gestational diabetes and no history of congenital anomalies in the family. The other sibling was also doing well. According to birth records, the baby cried immediately after birth, and had an Apgar score of 10 at 5 minutes. The Birth weight was 2.75 kgs. The baby passed meconium (in a small amount) immediately after birth; and passed urine 6 hours after birth. Feeds were initiated, but the baby developed complaint of vomiting on day 2 of life, which was bilious and non-projectile in nature. Vomiting gradually became persistent to 6-7 episodes/day, and the patient developed epigastric fullness by day 4 of life. Feeds were withheld. The baby was referred on day 12 of life. The baby's weight on presentation was 2.5kg and he was dehydrated. The apex beat was located in the 5th inter costal space, mid-axillary line anteriorly. There was no evident cyanosis and murmur. According to the referral slip, there were no episodes of apnoea or cyanosis; and there was a history of very infrequent passage of stools over this span of life.

A plain babygram showed the presence of double-bubble sign, the remaining bowel loops were devoid of gas; so a working diagnosis of duodenal atresia was made. The electrolytes were deranged. Coagulation

profile and liver function tests were within normal limits. Septic screen was negative.

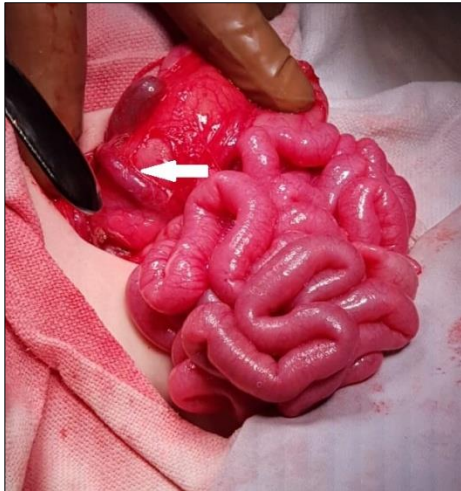


Figure 1: Intra-operative image of the Duodenal Atresia with pre duodenal portal vein (Arrow).

The patient was rehydrated, electrolyte imbalance was corrected. Patient underwent laparotomy after 48 hours of optimization. There were no hypoxic events during this period. Exploration of the abdomen was done via supraumbilical transverse incision, and it revealed type 1 duodenal obstruction (duodenal web), intact mesentery, PDPV which was partially obstructing, DJ was found right to the midline, duodenal C-loop was incompletely formed (Figure 1) which was also tethered by congenital adhesive bands (Ladd's bands), ileo-caecal junction was free floating, mesentery was narrow based. Duodenum was Kocherized. The web was appreciable with tactile feedback in second part of duodenum. Duodenum was opened transversely in dilated part and longitudinally in distal collapsed part. Web was located distal to opening of bile ducts and proximal to PDPV. Web was excised and Duodenoduodenostomy was done after confirming distal patency. Mesentery was widened, Ladd's bands were divided. Gastrojejunostomy was added to the procedure in view of partial obstruction caused by PDPV distal to Duodenoduodenostomy. Trans-anastomotic naso-jejunal tube was kept with the intent of early feeding. Small bowel loops were kept towards right, and large bowel loops were repositioned towards left side of the abdomen. A glove drain (cut out of latex non-powdered surgical gloves) was kept intra peritoneally in the vicinity of anastomosis, and the abdomen was closed in standard fashion. The child was extubated post-surgery and shifted to neonatal surgical intensive care unit.

The child was apparently doing well in the immediate post-operative period. Septic screen was negative post operatively. Abdominal X-ray on post-operative day (POD) 2 showed satisfactory gas pattern. Child passed stool on POD-3, and feeds were initiated the same day

via trans-anastomotic naso-jejunal tube. However, on POD-4, child had a sudden desaturation episode. Child was intubated. On auscultation, there were no crepitations. Endotracheal suctioning aspirates were also not suggestive of any aspiration event. Chest X-ray after intubation did not show any pulmonary infiltrates.

Cardiac pathology was suspected, and echocardiography was done. Echocardiography findings were suggestive of dilated right atrium and ventricle, mitral valve atresia, left ventricular hypoplasia, small aorta. Attendants were prognosticated by cardiology and cardiothoracic surgery team. Efforts were directed towards palliation. Prostaglandin (PGE1) infusion was started. Ventilatory supports were continued and were titrated in accordance with blood gas analysis. Feeds were withheld, and fluid support and total parenteral nutrition were continued. However, in spite of all palliative measures and supportive care, child succumbed to the cardiac anomaly and expired on POD-7.

DISCUSSION

Congenital duodenal obstruction can be due to either intrinsic or extrinsic pathologies or both. In our patient, the obstruction was both intrinsic (duodenal web) and extrinsic (malrotation and PDPV). The prognosis of DA used to be poor in the past. However, the survival rate has improved significantly over a while. This can be attributed to the advent of modern anaesthesia, a better understanding of pathophysiology, and intensive care units. The survival is quite promising (>90%) when it occurs as an isolated entity. Mortality is predominantly attributed to associated anomalies, especially complex cardiac anomalies.[3]

An association of intestinal malrotation in 64%, pancreatic anomalies in 22%, and situs inversus in 26% has been reported in cases of duodenal obstruction accompanied by PDPV.[4] Also, the association of cardiac anomalies has been reported in 20% of cases.[5]

Embryologically, duodenal atresia is due to an error in re-canalisation of the duodenum. The portal vein is formed by the caudal part of the left vitelline vein, the retroduodenal anastomosis, and the cranial part of the right vitelline vein. The superior mesenteric vein and splenic vein are formed from left vitelline vein, and they could be situated dorsally or ventrally to the fourth part of duodenum. Variations in the position of the portal vein may result from an anomaly of obliteration or an abnormal rotation. Persistence of caudal anastomosis can probably explain the association of PDPV with malrotation. The embryological basis of malrotation could be variable lack of rotation of the gastroduodenal bloc and the intestinal loop. However,

it is difficult to comment whether the preduodenal position of the portal vein is due to regressions of the vitelline veins and their anastomoses, or the result of abnormal rotation of the gastroduodenal or intestinal loop, or it is a combination of both.[6]

Hypoplastic left heart syndrome (HLHS) is a prototypical single right ventricle, presentation ranging from mitral and aortic stenosis with left ventricular hypoplasia to almost complete absence of the left heart structures with aortic and mitral atresia. The ascending aorta is typically small (1-2mm) in these cases and is perfused through retrograde aortic arch flow provided by the PDA.[7] HLHS occurs secondary to left ventricular outflow tract obstruction resulting in compromised and poorly orchestrated ventricular growth and development. In addition, during later stages of gestation, cardiomyocytes undergo a switch in myogenic potential and lose the ability to undergo mitosis. Ventricular hypoplasia can no longer occur, remodelling is instead limited to muscular hypertrophy.[8] In HLHS, pulmonary edema and congestive heart failure can develop in the first week of life. Circulatory shock and progressive hypoxemia and acidosis result in death, usually in first month of life. Without treatment this syndrome is fatal in 100% of cases, with 95% of patients dying during the first month of life.[9] Medical treatment is directed at maintaining ductal patency and balancing systemic and pulmonary blood flow; and possible manoeuvres include deliberate hypoventilation, low inspired oxygen concentration and additional carbon dioxide in an attempt to increase pulmonary vascular resistance (PVR) and limit pulmonary flow. PGE1 infusion may temporarily improve HLHS by reopening the ductus arteriosus, and it was attempted in our case too. Surgery in the newborn period is the only realistic option for long term survival.[10]

Because of resource constraints and logistic issues, it is our institutional policy to get bedside preoperative echocardiography only for patients having 1) Cardiac anomaly diagnosed during antenatal evaluations, 2) Murmur on auscultation, 3) Abnormal cardiac shadow on chest X-ray, 4) History of any cyanotic or desaturation episodes. None of the mentioned findings were present in the index patients, and

hence echocardiography was not done pre-operatively. Had it been done pre-operatively, attendants would have been counseled and prognosticated accordingly; as this syndrome is associated with high morbidity and mortality. In case they were still willing for surgery, PGE1 infusion could have been started preoperatively. In our case, by the time PGE1 infusion was started, the patient had already reached the age of physiological closure of patent ductus.

According to available records, the pregnancy was considered of low risk for cardiac malformations and the perinatal transition was uneventful. Therefore, in this case, the diagnosis of this complex cardiac anomaly was made postoperatively, which greatly decreased the chance of survival.

Despite the current improved knowledge about management and surgical treatment of HLHS, it is still associated with high mortality. Delayed diagnostic suspicion results in unsuccessful therapeutic intervention, even though the real impact of early diagnosis and intervention on mortality and quality of life of patients is still uncertain.

To conclude, dealing with duodenal atresia along with malrotation and PDPV can probably be dealt with satisfactorily in today's era. Gastrojejunostomy can be considered as a pertinent option in such subset of patients. However, associated severe cardiac malformations are usually the cause of death in these neonates. In case if more cases are reported with this specific set of congenital anomalies in association with duodenal atresia, it may point towards a new syndrome. Further, genetic and chromosomal studies can be helpful in this regard.

Acknowledgements: Nil

Conflict of Interest: None declared

Source of Support: Nil

Consent to Publication: Author(s) declared taking informed written consent for the publication of clinical photographs/material (if any used), from the legal guardian of the patient with an understanding that every effort will be made to conceal the identity of the patient, however it cannot be guaranteed.

Author Contributions: Author(s) declared to fulfill authorship criteria as devised by ICMJE and approved the final version.

REFERENCES

1. Applebaum H, Sydorak R. Duodenal atresia and stenosis-annular pancreas Chapter81. In: Coran AG, Caldamone A, Adzick NS, Krummel TM, Laberge JM, Shamberger R (Eds). *Pediatric Surgery*. 7th ed. Philadelphia, PA: Elsevier Inc; 2012. p1051-58.
2. Kim S, Cho Y, Kim H. Preduodenal portal vein: a 3-case series demonstrating varied presentations in infants. *J Korean Surg Soc*. 2013;85:195-7.
3. Choudhry MS, Rahman N, Boyd P, Lakhoo K. Duodenal atresia: associated anomalies, prenatal diagnosis and outcome. *Pediatr Surg Int*. 2009;25:727-30.
4. Wabada S, Abubakar AM, Mustapha B, Pius S, Khalil J, Abana AK. Congenital duodenal obstruction due to duodenal atresia with preduodenal portal vein, annular pancreas, and intestinal malrotation associated with situs inversus abdominis: A case report. *J Pediatr Surg Case Rep*. 2015; 3:545-47.

5. Mirza B, Sheikh A. Multiple associated anomalies in patients of duodenal atresia: a case series. *J Neonatal Surg.* 2012; 1:23.
 6. Mboyo A, Khadir SK, Guillaume MP, Massicot R, Flurin V, Lalioui A, et al. An exceptional cause of duodenal obstruction detected antenatally: A compressive preduodenal portal vein. *J Pediatr Surg Case Rep.* 2013; 1:420-24.
 7. Charles DF, Lauren CK. Pediatric Surgery. Chapter 66. In: Townsend C, Beauchamp R, Evers B, Mattox K(Eds). *Sabiston textbook of surgery.* 20th ed. Philadelphia PA: Elsevier Inc; 2016. p1619-57.
 8. Hickey EJ, Caldarone CA, McCrindle BW. Left ventricular hypoplasia: a spectrum of disease involving the left ventricular outflow tract, aortic valve, and aorta. *JACC.* 2012;59:S43-S54.
 9. Ferreira CR, Aiello VD, Melo AMAGP, Mota LB, de Carvalho ANC, SouzaHSP, et al. Classic form of hypoplastic left heart syndrome diagnosed postnatally: an autopsy report. *Autopsy Case Rep.* 2014;4:21-30. <http://dx.doi.org/10.4322/acr.2014.025>.
 10. Wernovsky G, Bove EL. Single ventricle lesions. In: Chang AC, Hanley FL, Wernovsky G, et al, eds. *Pediatric Cardiac Intensive Care.* Baltimore, Md: Williams & Wilkins; 1998:271-287.
-